



RAJIV GANDHI CANCER INSTITUTE & RESEARCH CENTRE

Vol. XIV

No. 12

Newsletter

Price : 50 Paise
Issue : Dec. 2011

SECTOR-V, ROHINI, DELHI-85 • Tel. : 47022222 (30 Lines) 27051011-1015, Fax : 91-11-27051037

EDITORIAL

ARE WE THE HEALERS?

When doctors look at their patients, they are trained to see only the disease. Doctors who think they can cure the disease without caring for the patient may be excellent technicians but they are incomplete doctors because they have an incomplete understanding of the disease. Doctors must understand that disease is more than just a clinical entity. Busy Doctors take down the medical history without paying much attention to the patient. But we must never forget the look of the patient's face, the trembling hands and the faltering speech, all potential signs of what really troubles him. The non verbal cues may be more important than the verbal physical ailment.

We as oncologists feel very happy by seeing long term survivors. We feel patient is cured of physical ailment. But we tend to forget the non-physical component of ailment. We may be addicted to seeing our physically cured patients but imagine the sense of insecurity, fear and psychosocial problems which these patients face.

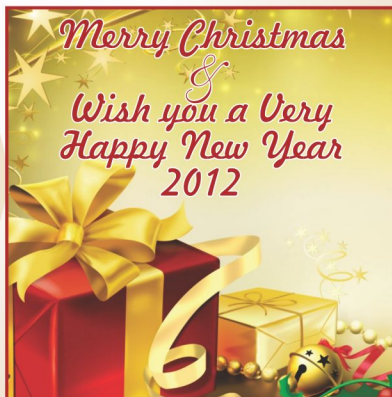Our patients find us completely inhuman. Doctors see X-Rays and prescribe pills. We need to teach young doctors how to touch and talk to people which is almost completely neglected in medical colleges. Doctors are actually called healthcare providers but we are only disease cure providers.

We use medical terminology which puts incredible emotional impact on patients. Lab reports and statistics often are used to take away hope. I heard one of the residents saying that statistically you are supposed to die. "Statistics are for dead people. Patient is not dead. Don't let statistics tell the patient

when to die". Statistics is useful to help in selection of best treatment option. Relations of patients understand that death does not mean that either your patient or you were a failure. I remember, daughter of one of my patient came with her sister few days after demise of her mother. She said you cared for my mother. She succumbed to cancer, not cured but cared. Please take care of my sister. We are indebted to you for providing our mother with the most effective medicine e.g. sincere care and love.

Let us treat our patients not as adversaries but as joint participants in a healing process. We are not true healers but let us facilitate healing of our patients. Let them feel that we may not cure but we care.

Dr. A. K. Dewan
Medical Director





CYSTIC LESIONS OF PANCREAS

Cystic lesions of the pancreas are increasingly being recognized due to the widespread use of cross-sectional imaging and this has led to a rise in the number of pancreatic surgical resections. However, because many cystic lesions are benign, in several instances resection may be unjustified. Therefore, it is important to characterize cystic neoplasm and to distinguish it from pseudocyst. The initial evaluation of a pancreatic cyst should be directed toward exclusion of a pseudocyst. Patients with pseudocysts generally have a history of acute or chronic pancreatitis, whereas those with cystic tumors most often lack such a history.

Pancreatic cystic neoplasms, despite increased recognition remain rare and represent approximately 10% to 15% of primary cystic masses of the pancreas. Over 70% of cystic neoplasms are discovered incidentally during the work up for abdominal pain, diarrhea, and other nonspecific gastrointestinal symptoms. The ratio of benign to malignant lesions is approximately 2:1. Cystic neoplasms are found in females at a ratio of 2:1 to 3:1 compared with males.

Causes of cystic lesions of pancreas are given in Table 1.

Table 1-Classification of Cystic Pancreatic Lesions

Pseudocyst

Common cystic pancreatic neoplasms

Serous cystadenoma

Mucinous cystic neoplasm

IPMN

Rare cystic pancreatic neoplasms

Solid pseudopapillary tumor

Acinar cell cystadenocarcinoma

Lymphangioma

Hemangioma

Paraganglioma

Solid pancreatic lesions with cystic degeneration

Pancreatic adenocarcinoma

Cystic islet cell tumor

Metastasis

Cystic teratoma

Sarcoma

True epithelial cysts

Serous cystic neoplasms (SCN):- Serous neoplasms are distributed evenly throughout the pancreas and are almost universally found incidentally. The tumors cause symptoms only if they are very large (>15 cm), usually compressive symptoms from a mass effect such as jaundice or gastric outlet obstruction. Serous tumors tend to be found more often in older women. They usually carry no risk of invasive cancer. Serous neoplasms are microcystic and have thin-walled septae that produce the typical "honeycomb appearance" On CTscan, these neoplasms will have a thin

wall and a typical sunburst pattern of calcification with a central, late-enhancing scar. Serous neoplasms never communicate with the main pancreatic duct.

Mucinous cystic tumors: mucinous cystadenomas and mucinouscystadenocarcinomas:- Mucinous tumors are usually seen in the body or tail of the pancreas, most frequently in women in their fifth or sixth decade of life. The tumors are circumscribe dunilocular or multilocular cysts with no communication with the pancreatic duct. CT scan will show a cyst with a thick wall and possible calcification within the wall. Malignancy risk is directly related to an increase in size and duration of existence. MCNs have a malignant potential ranging from as low as 6% to as high as 36%. Approximately 65% of the epithelium is composed of mucin-producing cells. Ovarian-like stroma that usually stains positive histologically for estrogen and progesterone receptors is found.

Intraductal Papillary Mucinous Neoplasm:- It is a papillary mucin-producing neoplasm that arises in the main pancreatic duct or major branches. IPMNs have direct communication with either the main pancreatic duct or the smaller branch ducts, and are most commonly found in the head or proximal region of the pancreas with equal distribution between sexes. IPMNs are divided into main duct IPMNs or branch duct IPMNs. Mixed type (which is present approximately 40% of the time) are considered mainduct for the purpose of prognosis and treatment. Branch duct tumors are more commonly found in younger patients and have a lower malignant potential. Noninvasive IPMNs are divided into low-grade dysplasia (adenoma), moderate dysplasia (borderline IPMN), and high-grade dysplasia or carcinoma in situ. Malignancy is found in 58% to 92% of main duct tumors. Malignancy is much less common in branch duct tumors (6% -46%). Also IPMNs have a higher risk of synchronous or metachronous primary extrapancreatic tumors.

Solid Pseudopapillary tumor-

Also known as solid papillary epithelial neoplasms, solid and cystic papillary tumors, and Hamoudi or Frantz tumors. SPTs are epithelial neoplasms of low malignant potential. They usually start as solid tumors and undergo massive degeneration giving rise to a cystic appearance on radiological imaging. SPTs are usually large lesions (>10 cm), well-demarcated and may occur anywhere within the pancreas. They have malignant potential. SPTs are found almost exclusively in young females with a mean age of around 30 years. Patients typically present with vague abdominal pain occasionally associated with weight loss, anorexia and a palpable abdominal mass. Radiologically, SPTs have a range of appearances from solid to cystic but typically, they present with a combination of these features, appear well marginated and may have central calcification.

Dagnosis:-

Once detected on imaging (CT or MRI), we have to first differentiate tumors from pseudocysts and then subtype



the tumors. The type of cyst wall seen, presence of a multilocular versus unilocular cyst, appearance of septations or solid components, pattern of calcification and simultaneous lymphadenopathy can all help make an accurate diagnosis. The availability of EUS +/- FNA and cystic fluid analysis has led to much improved understanding and characterization of these lesions. EUS criteria for mucinous /malignant neoplasms include size greater than 2 cm, pancreatic duct dilation, the presence of wall calcifications, and perhaps most importantly the presence of a frank mass or mural nodule. In cases that remain difficult to diagnose despite radiologic studies, cyst fluid analysis can help. Analysis includes cyst epithelial cell staining, stains for mucin, amylase levels, and tumor markers. Several proteins in the cyst fluid including CA19-9, CEA, CA125, and CA72-4 have been studied. Among these single most important tumor marker is CEA. Currently no standardized cut off level for CEA exists, however most centers use a CEA level of 192 ng/mL.

Treatment –

Serous neoplasms- Surgical treatment is not indicated in these unless the patient has obstructive symptoms or symptoms from local compression of surrounding structures. Larger tumors that are more than 4 cm are commonly associated with local symptoms. Therefore, in excellent surgical candidates without significant comorbidities, surgical resection is a reasonable option for tumors that are 4 cm or greater.

Mucinous neoplasms-

All MCNs must be considered premalignant and can undergo malignant transformation at any time. Therefore, the general recommendation is to resect all mucinous tumors, given the patient is an acceptable surgical risk. Because more than 90% of mucinous neoplasms are found in the body or tail of the pancreas, a distal pancreatectomy is the usual surgery.

Laparoscopic pancreatectomy is appropriate if there is a low risk of invasive cancer, the cyst is small (<3 cm), and there is no evidence of mural nodules or calcifications. Laparoscopic distal pancreatectomy with or without splenectomy safe and acceptable for these lesions.

IPMN-

Because of high risk of malignancy, all main duct IPMN should be resected. A pancreaticoduodenectomy or distal pancreatectomy is the proper treatment based on tumor location. Smaller branch duct IPMN can be kept on follow up or undergo conservative resections. Close observation is appropriate for branch duct IPMNs smaller than 30 mm, without symptoms, suspicious radiologic findings, or mural nodules. Indications for surgery in IPMN include- (1) main pancreatic duct type IPMN (includes mixed type tumors); (2) branch duct IPMNs with cyst diameters of over 30 mm or cyst diameter of 10 to 30 mm with a mural nodule; (3) IPMNs with a dilated main pancreatic duct; and (4) cytology-positive IPMN.

Solid Pseudopapillary Tumor-

Formal resection with curative margins is essential to ensure the best possible long-term survival. An aggressive approach is justified regardless of tumour size or metastatic spread.

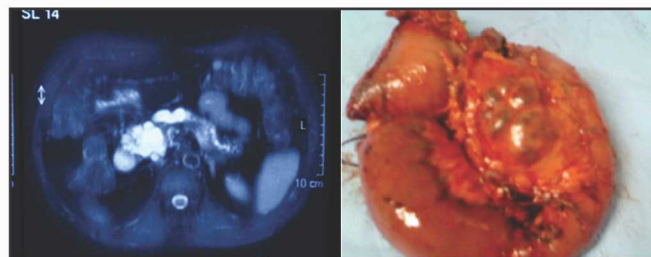
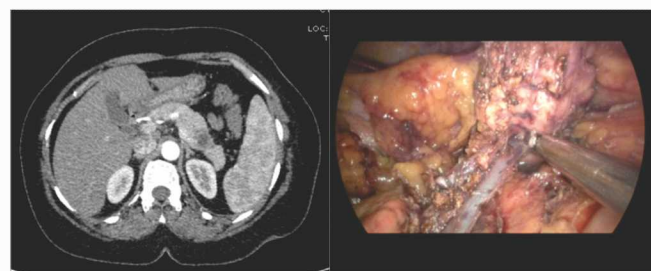


Fig 1 : IPMN-a-MRI b-Whipple's specimen



**Fig2a : Cystic tumor in tail of pancreas
2b : Laparoscopic Splenic vessel preserving
distal pancreatectomy (in process)**

Dr. Shivendra Singh

Senior Consultant & Chief
GI Oncosurgery & Liver Transplant

ROLE OF ENDOSCOPIC ULTRASOUND IN GASTROINTESTINAL MALIGNANCIES

Endoscopic ultrasound (EUS), a technique which combines endoscopy with ultrasound, is a well established modality. Echoendoscopes are of three types- radial array, linear array and mini probes. The radial scopes provide 360 degree cross sectional view of the structures. They primarily have diagnostic role, especially in staging tumours. With the introduction of linear array endoscopy including large channel scopes, it has become possible to do fine needle aspiration of the lesions for tissue diagnosis and to do therapeutic procedures. Mini probes are used for evaluation of bile and pancreatic ducts and in non passable esophageal cancers. EUS is a relatively safe procedure performed under intravenous sedation or short anaesthesia. EUS is meant for evaluation of luminal pathologies, submucosal and periluminal pathologies and FNA of suspicious lesions. Indications for EUS include the following:

1. Staging of cancers of oesophagus, stomach, pancreas, bile duct, ampulla of vater and rectum.
2. Evaluation of submucosal lesions
3. Evaluation of extramural impressions
4. Evaluation of pancreatic lesions
5. Evaluation of thickened gastric folds
6. Evaluation and EUS guided FNA of lesions adjacent to esophagus, stomach, duodenum and rectum



7. Chronic pancreatitis
8. EUS guided drainage of pancreatic pseudocysts
9. Celiac plexus block
10. Evaluation of anal sphincters in anal incontinence

ROLE OF EUS IN GASTROINTESTINAL MALIGNANCIES

Esophageal cancers

Treatment and prognosis of patients with esophageal cancers depends on accurate staging. Patients found to be negative for metastasis on PET/CT should undergo EUS for accurate T and N staging. EUS is superior to PET scan for nodal involvement particularly peritumoral and celiac lymph nodes. Sometimes, EUS can also pick up occult liver metastases. Patients with superficial lesions can be treated by endoscopic mucosal resection while patients with T3 or N1 can be given preoperative RT/CMT

Pancreatic cancers

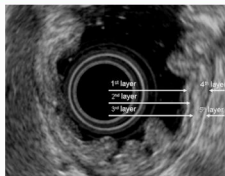
EUS is the most sensitive technique for detection of benign and malignant pancreatic masses. It can pick up lesions smaller than 2cm. It also provides tissue by FNA for accurate diagnosis. It is most accurate in T and N staging. It is also superior to other techniques in picking vascular invasion. In patients with cystic lesions, it helps in differentiating pseudocysts from true cystic pancreatic neoplasms. It helps in categorizing cystic lesions based on their morphology and fluid characteristics. Severe unremitting abdominal pain is common feature in late stages. Celiac plexus neurolysis under EUS guidance provides good short term results.

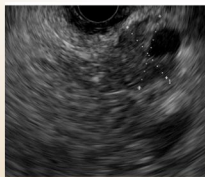

Fig. 1 - Hypoechoic mass in the head of pancreas

Gastric tumours

EUS plays important role in loco regional staging and is superior to CT scan. But, compared to esophageal cancer, it is less sensitive. It is also very useful in cases of gastric lymphoma.



**Fig.2
EUS examination of
normal gastric wall**

Rectal cancers

As with most cancers, treatment of rectal cancer depends on stage. EUS is superior to CT and MRI for tumour size and depth and nodal involvement. In a prospective study, EUS changed management in 31% of patients.

Submucosal lesions

Diagnosis of submucosal lesions of the gastrointestinal tract is one of the main indications for EUS. It not helps in finding the layer of origin of tumour, but also allows tissue sampling by FNA. It also differentiates submucosal lesions from extraluminal lesions.

Summary

EUS is a versatile technique combining endoscopy and ultrasound. It is very useful in loco regional staging of GI cancers. It also helps in acquiring tissue by FNA. Therapeutic indications include CPN, placement of markers in pancreatic tumours for local RT and bilio-enteric anastomosis / biliary drainage.

Dr. Arvind K. Khurana

MD,DNB,DM,FRCP - Sr. Consultant, Gastroenterology

Latest Addition in Diagnostics :
**OLYMPUS ENDOSCOPIC AND
ENDOBRONCIAL ULTRASOUND**

Editor : Dr. A. K. Dewan

EDITORIAL BOARD

- * Mr. D. S. Negi (C.E.O.)
- * Dr. A. K. Chaturvedi
- * Dr. D. C. Doyal
- * Dr. Gauri Kapoor
- * Dr. Anurag Mehta
- * Dr. S. A. Rao
- * Dr. P. S. Choudhury
- * Dr. A. Jena
- * Dr. S. K. Rawal
- * Dr. Kapil Kumar
- * Dr. Sunil Kr. Gupta
- * Dr. B. K. Nathani
- * Dr. Rupinder Sekhon
- * Dr. (Col.) A. K. Bhargava
- * Dr. R. S. Jaggi
- * Dr. Vineet Talwar
- * Dr. Sandeep Mehta
- * Dr. Sheh Rawat
- * Dr. S. K. Sharma
- * Dr. Amitabh Sandilium
- * Dr. Shivendra Singh
- * Dr. Swarupa Mitra

To, _____

Printed & Published by Mr. K. K. Mehta on behalf of Indraprastha Cancer Society & Research Centre and Printed at Raju Art Printers, 18-A, Old Gobind Pura Extn., Street No.2, Parwana Road, Delhi-51, Tel.: 9871006333

Published from RGCI&RC, Sector-V, Rohini, New Delhi-110085 • Editor: Dr. A. K. DEWAN

If undelivered please return to :

**RAJIV GANDHI CANCER INSTITUTE
& RESEARCH CENTRE**

Sector-V, Rohini, Delhi-110085