



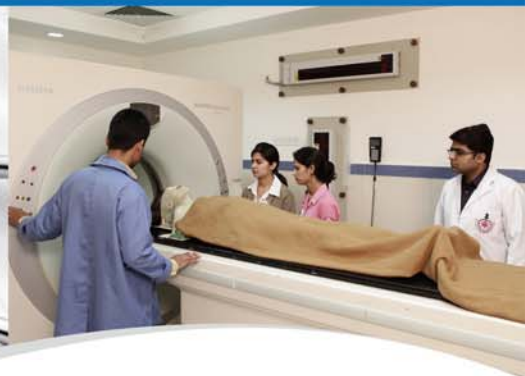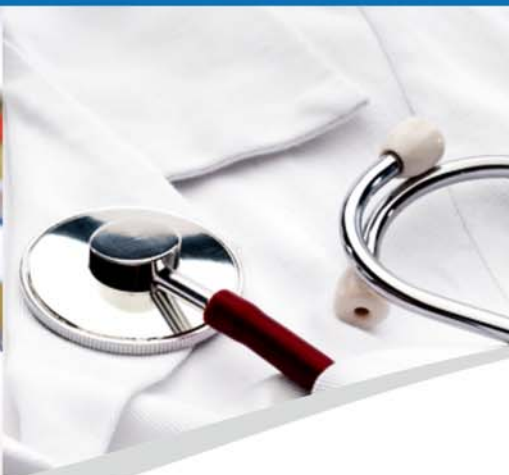CANCER NEWS

ISSN 0973-9653

Vol 6

No 5

December 2012



**Rajiv Gandhi Cancer Institute
and Research Centre**

A Unit of Indraprastha Cancer Society
Registered under "Societies Registration Act 1860"

www.rgcirc.org

From the Desk of Director Research

Cancers of the brain or central nervous system can arise from primary brain cells, known as primary brain cancer, or from the growth of cancer cells that develop in other organs, termed as metastatic brain cancer. It is important to differentiate whether this cancer originates in the nerve cells or spreads from the other organs in order to determine the treatment options. Classification of primary brain tumors by the WHO is based on their cellular origin and histologic appearance. Neuroglial tumors, which account for more than 80% of primary brain tumors, originate from astrocytes, oligodendrocytes, or ependymal cells. The precise incidence and prevalence of brain tumors is poorly understood and documented because benign tumors were not reported earlier. Metastatic disease to the brain, which accounts for the highest number of CNS tumors, also remains unreported. Worldwide the incidence and mortality of primary CNS tumors is 15.7 and 11.1 per 100,000 people per year respectively-2008 data.

There is no specific or singular clinical symptom or sign for any brain tumor. However, swelling, or obstruction of the passage of cerebrospinal fluid from the brain may cause early signs of increased intracranial pressure which translates clinically into headaches, vomiting, or an altered state of consciousness. Imaging, such as computed tomography scans and especially magnetic resonance imaging, plays a central role in the diagnosis of brain tumors. The recent advances in brain tumor imaging offer unique anatomical as well as pathophysiological information that provides new insights on brain tumors, directed at facilitating therapeutic decisions and providing information regarding the prognosis.

Over the past few decades, novel therapies for patients with brain tumors are being developed. Although surgical resection is the cornerstone of treatment, postoperative radiation and chemotherapy may improve survival in patients with high-grade brain tumors. High precision radiotherapy technology certainly improved the radiation dose delivery to the tumor sparing the normal tissue. Recent advances in targeted therapy offer novel treatment options for patients who experience recurrence of the primary brain tumor. Bevacizumab (Avastin) has been approved in the United States and over 30 countries worldwide for the treatment of glioblastoma.

More recent work on understanding the molecular mechanisms and gene mutations combined with clinical trials are leading to promising and tailored therapeutic approaches. Multiple challenges remain, including tumor heterogeneity, tumor location in a region where it is beyond the reach of local control, and rapid, aggressive tumor relapse. Therefore, the treatment of patients with malignant brain tumors should encompass multimodality management, including surgery, radiotherapy, chemotherapy, and targeted therapy.

This issue of Cancer News is based on the theme of Brain Cancer, and includes regular articles under the sections “Special Feature”, “Guest Article”, “Perspective”, “New Technologies”, “Clinical Trials”, “Cancer Control”, “Globe Scan”, and “In Focus”. We appreciate the contribution made by Dr Rana Patir, Director and Head Department of Neurosurgery, Fortis Memorial Hospital, Gurgaon, for providing the “Guest Article”.

Suggestions/comments from the readers are welcome. Wishing our readers a Happy, Prosperous and Healthy New Year 2013!

Dr D C Doval

CONTENTS

- **Special Feature:** Contemporary Treatment and Controversies in the Management of High Grade Gliomas [3-6]
- **Guest Article:** Role of Surgery in High Grade Gliomas [7-9]
- **Perspective:** Impact of Advances in Radiation Oncology in the Treatment of CNS Tumors [10-12]
- **Cancer Control:** Brain Cancer Among Farm Workers; Parity, Age at First Birth, and Risk of Brain Cancer [12]
- **New Technologies:** Drug for Rare Pediatric Brain Tumor; Laser Technology to Fight Brain Tumor; New Surgical Probe for Brain Tumors; Spectroscopic ‘Fingerprints’ to Diagnose Brain Tumors [13]
- **Clinical Trials:** Bevacizumab and Irinotecan in Primary Brain Tumors; Dasatinib Plus Erlotinib in Recurrent Malignant Glioma; Treatment Options for Elderly Patients with GBM; Verubulin & Carboplatin in Relapsed GBM [14]
- **Globe Scan:** Working Memory and Facial Expression (China); Integrins and p53 Pathways (France); Epilepsy in the End-of-life Phase (Italy); Risk of Brain Tumors (USA) [15]
- **In Focus:** Methyl Guanine Methyl Transferase in CNS Tumors [16-18]
- **The Pink Ribbon Meet** [19]

Research & Analysis Team
Research Department

Published by: **Rajiv Gandhi Cancer Institute & Research Centre,**
Sector - 5, Rohini, Delhi - 110085, India

This publication aims at disseminating information on pertinent developments in its specific field of coverage. The information published does not, therefore, imply endorsement of any product/process/producer or technology by RGCI&RC.

SPECIAL FEATURE

CONTEMPORARY TREATMENT AND CONTROVERSIES IN THE MANAGEMENT OF HIGH GRADE GLIOMAS

High grade gliomas (HGG) account for ~70% of all gliomas and predominantly affect patients between 40-70 years of age. They are one of the most common tumors encountered in clinical practice at any neuro-oncology centre. They are diffusely infiltrating tumors, which according to the WHO classification, can be divided into anaplastic astrocytoma (WHO grade III), anaplastic oligodendroglioma (WHO III), anaplastic oligoastrocytoma (WHO grade III) and glioblastoma (WHO grade IV).

These tumours continue to have growth potential. There is no stable tumor and recurrence tends to be mostly at the site of the original disease or sometimes distant from the original site (multi-focal recurrence). The management of glioma has evolved considerably during the last decade as significant advances in surgery, cytotoxic chemotherapy, targeted biological therapy, and molecular tumor profiling have entered clinical practice. Although glioma remains a challenging disease with a dismal long-term prognosis, recent advances provide encouragement for the continued development of new treatment options

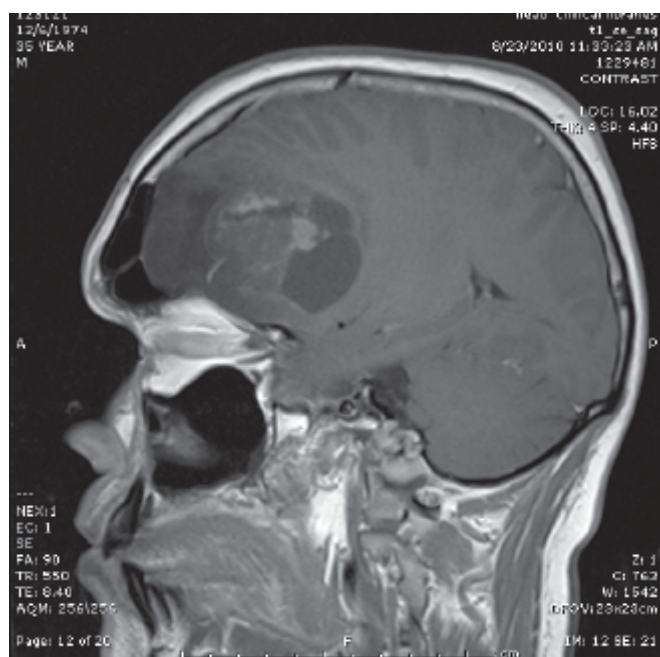
for these patients. The contemporary treatment and controversies in the management of high grade gliomas are discussed here.

Surgical Resection for Patients with Newly Diagnosed or Recurrent Glioma

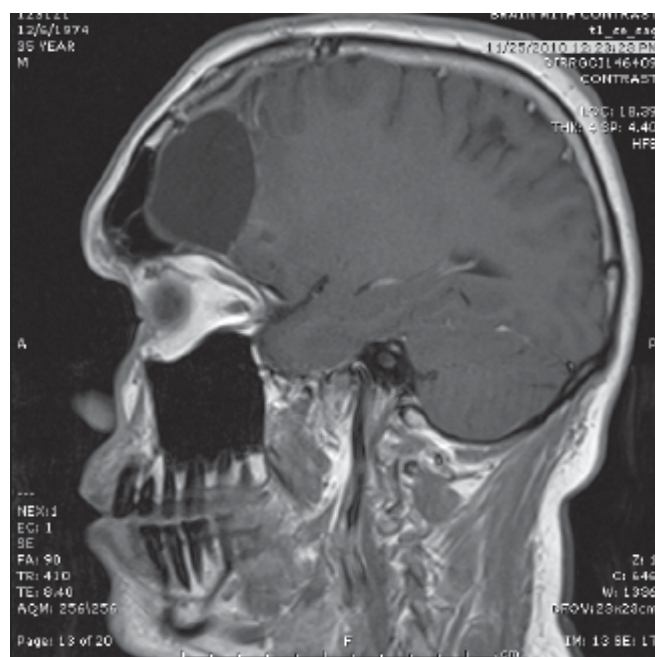
During the last decade, gross total resection (GTR) has increasingly been selected for patients with high grade gliomas and promising new strategies have been developed that combine local therapy, chemotherapy, and radiation.

Gross Total Resection

Surgical resection has traditionally been considered an option for relatively few patients with high grade glioma due to the poorly defined borders of these infiltrative lesions. More recently, GTR has increasingly been used for patients with high grade glioma. GTR was historically defined by the surgeon on the basis of operating room observations. In contemporary clinical practice, GTR is defined by post-operative magnetic resonance imaging (MRI) findings, including the degree of contrast enhancement or remaining fluid-attenuated inversion recovery (FLAIR) signal abnormality. MRI assessment must be performed within the first 1 to 3 days after surgery to avoid confounding the interpretation of images by post-operative inflammation and disruption of the blood-brain barrier (BBB). Gross total resection also has been used successfully in patients with poorly enhancing



Pre-op T1W contrast enhanced sagittal image of a left frontal glioblastoma



Post-op contrast enhanced T1W image of the same patient showing gross total resection of the lesion

or non-enhancing lesions, and for patients who were initially treated with subtotal resection but who had significant residual impairment. Techniques, such as intraoperative MRI, functional imaging, and awake craniotomy, are permitting more aggressive resections without neurologic injury. Several recent reports have described significant benefits of cytoreductive surgery for patients with gliomas that do not have substantial post-operative neurologic deficits. In addition to the potential benefits for patient quality of life, there is also evidence to suggest that surgical resection delays the time to glioma recurrence. Gross total resection also has been associated with several other benefits. Patients are likely to require less steroid treatment, which reduces the risk of several steroid-related adverse events, including cushingoid habitus, steroid myopathy, peripheral edema, and hyperglycemia. By increasing the amount of tissue available for pathologic examination, GTR may help to improve diagnostic accuracy. GTR also may help to improve seizure control and make it possible to administer local therapies (eg, BCNU wafers); it is increasingly being required in clinical trials of new immunotherapy regimens.

Local Therapy of Malignant Gliomas

BCNU-loaded wafers were approved for the treatment of newly diagnosed malignant glioma in 2003 and for recurrent GBM in 1996. Implantation of BCNU wafers after tumor resection provides local delivery of a high concentration of cytotoxic therapy that is not limited by penetration of the agent through the BBB. BCNU wafers may be considered for the treatment of focal tumors that are potentially treatable, using GTR, and that are not situated near critical functional brain areas. The use of BCNU wafers have recently been a controversial topic among neurosurgeons because some studies have questioned the effectiveness of this approach. Central nervous system (CNS) infection and wound infection have been reported in some patients, with reported rates varying from 2% to as high as 28%. Some patients develop pronounced brain edema. Otherwise, treatment is generally well tolerated and provides an alternative approach to multimodal therapy in patients who cannot tolerate systemic cytotoxic drugs.

Unresectable Cases: The Importance of Histology

It is usually possible to obtain a biopsy sample even when GBM is considered unresectable, and this sample may have a significant impact on the selection of a

treatment strategy. Development of technologies, such as a frame-based and frameless stereotactic biopsy has made it possible to obtain biopsy specimens from very deep brain regions that were once considered inaccessible, including the brain stem. In addition, a transfrontal contralateral approach has been used to successfully conduct biopsy, without significant morbidity, deep lesions of the brain stem and avoiding the surface of the tentorium. Hence, biopsy-guided therapy should be the standard regardless of whether the lesion is above or below the tentorium.

Use of Molecular Markers and Brain Imaging to Predict Glioma Course and Individualize Therapy

Temozolomide is the foundation of therapy for most patients with GBM. Considerable recent research has examined several genetic, molecular, and neuroimaging markers that may identify tumors that are especially susceptible or resistant to temozolomide therapy.

Genetic Markers

Temozolomide is an alkylating agent that targets N7 or O⁶ positions of guanine residues of DNA, resulting in interruption of cell division and subsequent cell death. MGMT and the closely related enzyme, O⁶-alkylguanine-DNA alkyltransferase, repair DNA damage by demethylating the O⁶ position of guanine. This returns guanine to its baseline state and allows cell division to continue. When the MGMT promoter is methylated, there is decreased MGMT transcription. When MGMT is highly expressed or unmethylated, it is better able to counter the effects of temozolomide and other forms of alkylating therapy. MGMT promoter methylation is prognostic of a better outcome with radiation and temozolomide concomitant therapy. Although MGMT expression and promoter methylation are important prognostic factors, there are potential limitations to the use of MGMT in treatment planning. MGMT testing is relatively complex, and there is no clear consensus on the optimal technique to evaluate MGMT activity. The polymerase chain reaction (PCR) procedure is widely considered the most sensitive and specific. The PCR technique requires cryopreserved tumor specimens to provide sufficient high-quality DNA which is not always feasible. In addition, MGMT status testing is not yet routinely paid for by health insurance plans. Patients are therefore often required to bear the cost of this additional test. Moreover, the correlation between test results and treatment outcome is not perfect, and there is considerable variability in the results due to factors, such as the location

of tissue sampled, the quality of the tissue, and how MGMT is assayed. Some studies reveal that methylation of the MGMT promoter is associated with overexpression of a mutant form of p53. This mutation increases tumor invasiveness and predicts a worse prognosis. Similarly, an inverse relationship between MGMT expression and activation of the tumor-suppressing protein phosphatase and tensin homolog (PTEN) has been described. Mutations of the isocitrate dehydrogenase genes *IDH1* and *IDH2* have recently been identified as important prognostic factors in patients with glioma. It is possible *IDH1* or *IDH2* may help identify subtypes of patients with anaplastic astrocytoma or secondary glioblastoma that have a lower likelihood of progression.

Imaging as a Predictor of Response

MRI with gadolinium contrast is an essential tool for evaluating areas with disrupted BBB but does not provide information about the specific cause of the disrupted BBB. Many other advanced imaging techniques have been proposed to predict who will respond to various treatments and distinguish treatment-related effects from tumor progression. Some of these techniques include magnetic resonance spectroscopy, apparent diffusion coefficient (ADC), amide proton transfer imaging, fluorodeoxyglucose positron emission tomography (PET), and new PET markers including ^{18}F -fluoroethyl-tyrosine, ^{18}F -fluorothymidine, ^{18}F FDOPA and ^{11}C -methionine. Disease progression, while on temozolomide, is often very difficult to determine with standard MRI techniques. ADC has emerged as a potentially significant marker of treatment response in patients who are being treated with inhibitors of angiogenesis. ADC is routinely reported with MRI results, and provides a measure of overall cell density. ADC signal is low in areas where cells are densely packed (eg, in developing tumors), whereas high ADC levels indicate tissue necrosis. A limitation of many of these imaging approaches is that they require technology that is available to very few research centers, are time consuming and expensive, and lack validation. Nonetheless, a critical limitation in the current practice of neuro-oncology is the accurate interpretation of tumor response.

Temozolomide and Radiation Therapy

The role of temozolomide in glioblastoma is supported by the results of a large clinical trial that was initially reported in 2005 in the *New England Journal of Medicine*, in which the addition of temozolomide to

radiotherapy was superior to radiotherapy alone in patients with newly diagnosed glioblastoma. A recent report of 5-year outcomes from this study demonstrated significant long-term benefits of temozolomide and radiation versus radiation alone regardless of patient age, extent of resection, or MGMT methylation status. Overall survival after 5 years was 9.8% with temozolomide and radiotherapy versus 1.9% with radiotherapy alone ($P < .0001$). The most common risks of combination therapy with temozolomide and radiation include hematologic adverse events such as thrombocytopenia and leucopenia. Changes in CD4+ cell count have also been increasingly recognized as an important factor in patients treated with temozolomide and radiation. It is unclear whether low CD4+ levels should lead to discontinuation of temozolomide, and if so, what should be the threshold CD4+ count for discontinuation.

The Emerging Role of Angiogenesis Inhibitors in the Treatment of Glioma

Treatments that target angiogenesis have been shown to produce several clinically significant effects in patients with glioma, including increased progression-free survival in patients with recurrent glioblastoma, reduced dependency on steroids, and reduction of intracranial pressure for some patients. Bevacizumab has been widely used in patients with recurrent or progressive malignant gliomas. Bevacizumab is generally well tolerated and has side effects that do not overlap with the cytotoxic therapies it is often paired with. However, angiogenesis inhibition has not been shown to significantly improve overall survival. It should also be noted that progression in clinical trials is measured using gadolinium enhancement on MRI. It is therefore possible that the reported effects of anti-angiogenesis therapy actually reflect an effect on the BBB, rather than a specific antitumor effect. There are also several potential limitations of anti-angiogenesis therapy. Inhibition of angiogenesis may change the natural history of glioblastoma. There is experimental evidence that tumors exposed to bevacizumab gain features of increased tumor invasiveness and migration. Bevacizumab is also relatively expensive and has thus far not been shown to improve overall survival in patients with glioma. Thus far, there is no therapy identified to effectively control the tumor after progression on bevacizumab. Moreover, both clinical reports and preclinical reports raise the possibility that bevacizumab may possibly change the behavior of some tumors, perhaps actually increasing the propensity for infiltration. With

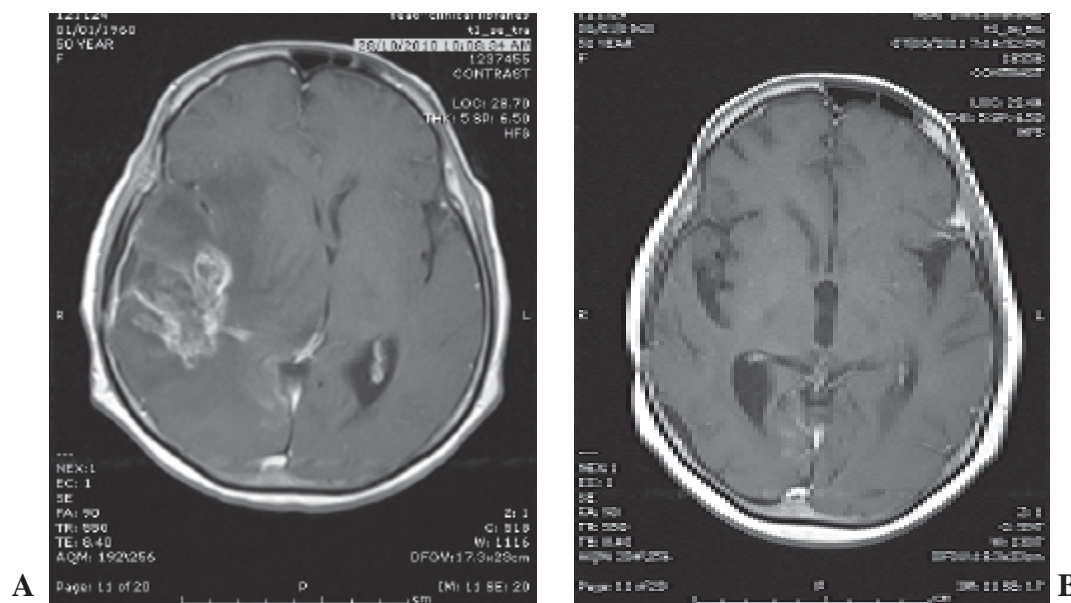


Figure 1: T1-weighted contrast enhanced axial MRI images (A) before Bevacizumab (B) after Bevacizumab showing decrease in contrast enhancement and brain edema after bevacizumab administration, thus improvement in MRI images but there was clinical worsening.

bevacizumab treatment, it is possible for the patient's symptoms and MRI findings to diverge over time, with the scan improving but symptoms worsening (Fig. 1). A multidisciplinary approach is essential for planning and coordinating surgical care, chemotherapy, radiation therapy, and supportive care, and for evaluating and interpreting the response to treatment. Management of treatment and disease related complications may have as great an impact on survival and quality of life as therapeutics, and may need careful attention.

Other Clinical Considerations in Glioma Management

Several other factors must also be considered in managing patients with glioma. *Hyperglycemia* is a common and potentially serious complication of glioma treatment. Patient mobility is often impaired as a result of *steroid-induced myopathy*, especially for patients who require high steroid doses for long periods of time. *Seizure* management is important to help maintain quality of life. Newer antiepileptic agents, such as levetiracetam, zonisamide, and topiramate, are often very effective and well tolerated, and are unlikely to interact with chemotherapy agents. Finally, a word about *pseudoprogression*. It describes a pattern of radiographic evidence of glioma progression immediately following treatment that is actually due to other causes, such as treatment-related inflammation, ischemia, infection, or seizures. Pseudoprogression occurs in as many as 20% of patients treated with temozolomide and radiation, and

may account for as much as 50% of the post-treatment MRI change in these patients. For this reason, most clinical trials now require that patients continue MRI assessments for at least 3 months after the completion of treatment to ensure that progression is due to glioblastoma rather than pseudoprogression. It can be really difficult to distinguish among the various potential causes of imaging changes using conventional imaging techniques.

(Dr Ramandeep Singh Jaggi, Consultant, Dept of Neuro Surgery)



MUSCULOSKELETAL ONCOLOGY UPDATE

Sunday, 3rd February 2013

Venue: India Habitat Centre, New Delhi

Outline of the program:

- " Introduction to normal musculoskeletal radiology & pathology
- " How, when and when not to do biopsy?
- " Benign tumors - tips and tricks
- " Soft tissue sarcomas - the controversies
- " Diagnosis and work up of bone tumors - the radiologist's perspective
- " Histopathological diagnosis of bone and soft tissue tumors - beyond microscope

Organized by:

Rajiv Gandhi Cancer Institute & Research Centre
Sector 5, Rohini, Delhi - 110085
Ph +91-11-4702 2478 | conference@rgcirc.org
www.rgcirc.org

GUEST ARTICLE

ROLE OF SURGERY IN HIGH GRADE GLIOMAS

Introduction

There is enough evidence that extent of tumor removal is an important indicator of prognosis for high grade gliomas (1,2,3). As much as 64% to 77% of patients undergoing conventional microsurgical tumor resection of high-grade gliomas who were thought to have a gross total removal, had residual disease (1,2). To achieve this goal various tools are available, some of which are based on image guidance and some on delineation of functional brain. Thus, we have neuronavigation intraoperative MRI, ultrasound, and fluorescence techniques (2-12). Last but not the least is the operating microscope, which with its coaxial lighting and magnification, provides unsurpassed visual input to identify abnormal tissue and anatomy.

Text

Extent of Surgical Resection: Surgery establishes histology, rapidly reduces cell mass and alleviates symptoms. Possibly the removal of resistant hypoxic tumor cells enhances the efficacy of adjuvant therapies. As early as 1959, it was noted that extensive excision, especially with the addition of radiotherapy, lead to greater survival (13). The benefit of extent of resection

has primarily been assessed in uncontrolled retrospective studies (class III evidence) (12,14–17). Ideally what is needed is a prospectively randomized trial to address the issues of extent of resection and outcome. There are only two such studies available to date by Vuorinen et al (18) and Stummer et al (2,3). The former study showed that median survival was significantly longer in patients who underwent resection than in those who were biopsied. It did not, however, answer the question whether the extent of resection effected prognosis.

Stummer investigated the usefulness of aminolevulinic acid (ALA)-induced fluorescence for improving resection and outcome in patients with malignant glioma. ALA, a metabolite in the heme biosynthesis pathway is taken up by malignant glioma cells where it is converted into strongly fluorescing porphyrins. Using surgical microscopes, violet-blue light used intermittently highlighted the tumor during surgery as a red tissue fluorescence. The frequency of complete resection was 65% in the 5-ALA surgery group (n=139) compared with 36% in the conventional surgery group (n=131) using white light. This is reflected in the overall survival of 15.2 versus 13.5 months respectively. This was level I data for 5-ALA increasing the probability of a complete resection and a level IIb evidence that extent of resection was an independent survival prognostic indicator. No threshold short of complete removal of contrast-enhancing tumor had an impact on survival. As the end point of surgery was the removal of all contrast enhancing tumor, intraoperative MRI is an indispensable tool in achieving this end.

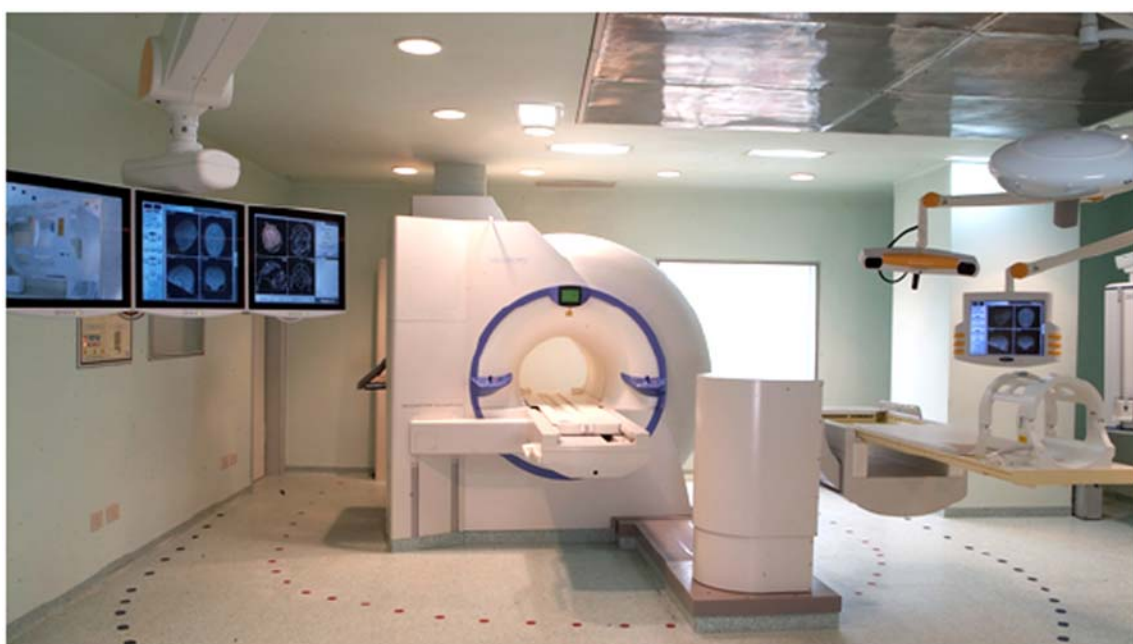

Fig1: Integrated operating theatre with a dedicated MRI unit in the same room

MRI Based Neuronavigation: MRI is the gold standard for the delineation of lesions of the central nervous system. In frameless neuronavigation, a preoperative MRI is registered to the physical space using the contours of the face which the computer “sees” using optical or electromagnetic feedback. A pointer or the focus of an operating microscope is then used like a 3-D mouse to identify any point in the registered physical space.

Functional Magnetic Resonance Imaging (fMRI)

Hyperperfusion related to neuronal activity is reflected as a greater concentration of oxyhaemoglobin compared with deoxyhaemoglobin. This is picked up in BOLD sequences which is then fused with structural images to give the familiar fMRI. This data correlates well with intraoperative cortical stimulation. Thus eloquent areas can be mapped, including the motor cortex, visual cortex, and language dominance. The inherent poor spatial resolution of fMRI which while helpful in guiding resections cannot be used for precise definition of the safe limits where direct cortical stimulation is more reliable.

Tractography

Diffusion tensor imaging (DTI) based fiber tracking or tractography identifies the subcortical white matter connections. This does not require the cooperation of the subject and can therefore be used to indirectly identify

the motor cortex of the paralysed limb. This is done by seeding the corticospinal tract at the cerebral peduncle and projecting it in a retrograde manner (20).

A space occupying mass can distort and displace fibre tracts. Wu et al in a prospective, randomized controlled trial had preoperative DTI scanning on 118 of 238 patients undergoing resection for high- and low-grade supratentorial glioma involving the pyramidal tracts (21). Using neuronavigation, gross total resection was achieved more frequently in the DTI group as compared to the control group (74.4% vs. 33.3%). This translated into improved survival, reduced mortality and improved 6-month Karnofsky Performance Scale score providing Class I evidence that fibre tract neuronavigation improved patient mortality and morbidity in glioma surgery.

Intraoperative Magnetic Resonance Imaging

The MRI is either integrated to the operating theatre as a dedicated unit in the same room (Fig 1) or as a shared resource in an adjacent room. High field MR units with field strength of 1.5 and more reduces acquisition times and the more homogenous magnetic field reduces distortions and improves spatial resolution. fMRI, DTI perfusion and spectroscopy sequences can also be performed intra-operatively (22,23). Ferromagnetic instruments can be used in the safe zone beyond the 5-

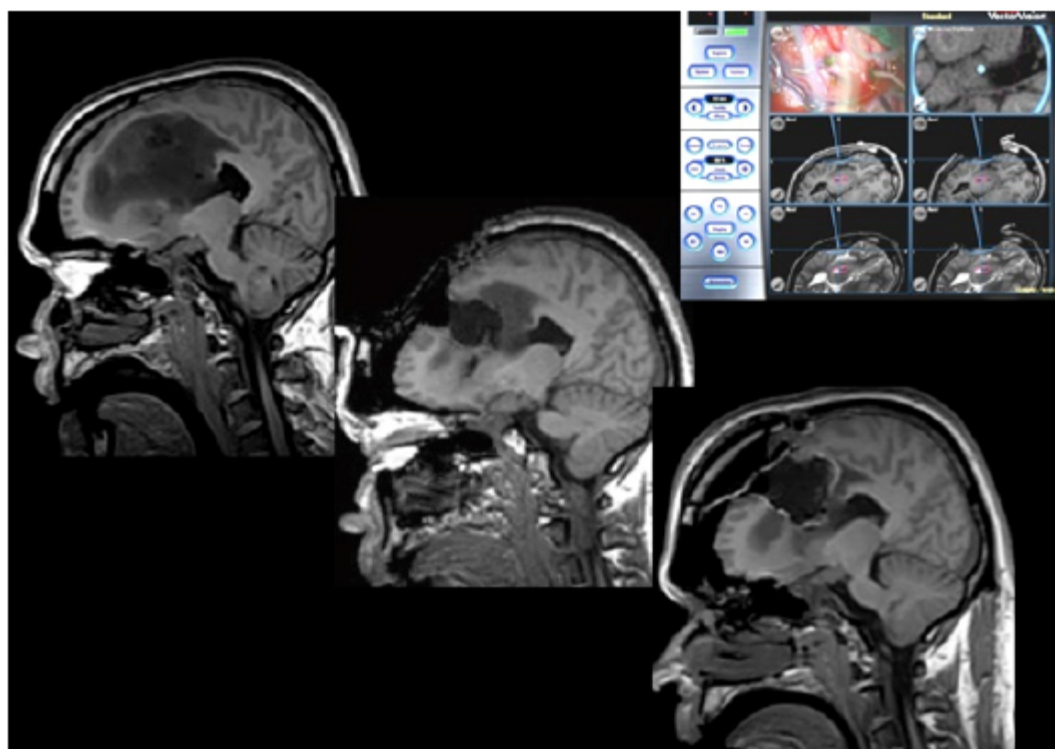


Fig 2: Serial images acquired before resection, during and in the completion of resection. Inset is a screen grab of the monitor displaying neuronavigation images and intraoperative video

gauss line demarcated on the floor. Pre- and post-contrast T1 images are used for intraoperative monitoring of brain shifts and residual disease in high grade gliomas (Fig 2). This is done as frequently as the surgeon feels the need for refreshing this input to take care of brain shifts during surgery related to tumor removal and CSF drainage. Contrast leakage to normal tissue increases over time and carries a risk of over resection. With intraoperative MRI, complete removals are doubled from 36.6% to 75.6% (24).

With each additional intraoperative image acquisition, the patient has to be specially draped before moving to the machine and again on returning to the operative field. This prolongs operative time and brings a risk of a break in the sterile field. Typically the duration of surgery is between 5-7 hours and may be longer if intraoperative neurophysiology is included.

Conclusion

The surgical goal in high grade gliomas is the removal of all contrast enhancing tumor. This has been the driving engine for the development of intraoperative MRI and integrated neuronavigation. With the availability of an increasing number of MRI sequences, the neurosurgeon has to balance the utility of each additional input against the time required for acquisition of data with its attendant risk of increased complications and infection. The prohibitive costs will remain a deterrent in its widespread use. ALA guided resections while being more cost effective have not caught on in our country because of the irregular supply.

References

1. Albert F.K., Forsting M., Sartor K., et al: Early postoperative magnetic resonance imaging after resection of malignant glioma: objective evaluation of residual tumor and its influence on regrowth and prognosis. *Neurosurgery* 1994; 34:45-60.
2. Stummer W., Pichlmeier U., Meinel T., et al: Fluorescence-guided surgery with 5-aminolevulinic acid for resection of malignant glioma: a randomised controlled multicentre phase III trial. *Lancet Oncol* 2006; 7:392-401
3. Stummer W, Reulen HJ, Meinel T, et al: Extent of resection and survival in glioblastoma multiforme: identification of and adjustment for bias. *Neurosurgery* 2008; 62:564-76.
4. Toda M: Intraoperative navigation and fluorescence imaging in malignant glioma surgery. *Keio J Med* 2008; 57:155-61.
5. Leuthardt E, Lim, Chris C H, Shah M, et al: Use of movable high-field-strength intraoperative magnetic resonance imaging with awake craniotomies for resection of gliomas: preliminary experience. *Neurosurgery* 2011; 69(1):194-206.
6. Schneider JP, Trantakis C, Rubach M, et al: Intraoperative MRI to guide the resection of primary supratentorial glioblastoma multiforme: a quantitative radiological analysis. *Neuroradiology* 2005; 47:489 - 500.
7. Truwit C.L., Hall W.A.: Intraoperative magnetic resonance imaging-guided neurosurgery at 3-T. *Neurosurgery* 2006; 58: ONS-338-45.
8. Nimsky C, Ganslandt O, Buchfelder M, Fahlbusch R: Intraoperative visualization for resection of gliomas: the role of functional neuronavigation and intraoperative 1.5 T MRI. *Neurol Res* 2006; 28:482 - 87.
9. Ji S., Wu Z., Hartov A., et al: Mutual-information-based image to patient re-registration using intraoperative ultrasound in image-guided neurosurgery. *Med Phys* 2008; 35:4612-624.
10. Sergeeva O., Uhlemann F., Schackert G., et al: Integration of intraoperative 3D-ultrasound in a commercial navigation system. *Zentralbl Neurochir* 2006; 67:197-203.
11. Lindner D, Trantakis C, Renner C, et al: Application of intraoperative 3D ultrasound during navigated tumor resection. *Minim Invasive Neurosurg* 2006; 49:197-202.
12. Stummer W, Novotny A, Stepp H, et al: Fluorescence-guided resection of glioblastoma multiforme by using 5-aminolevulinic acid-induced porphyrins: a prospective study in 52 consecutive patients. *J Neurosurg* 2000; 93:1003- 13.
13. Toennis W, Walter W: Glioblastoma multiforme (report on 2611 cases). *Acta Neurochir Suppl (Wien)* 1959; (Suppl 6):40-62.
14. Lacroix M, Abi-Said D, Fourney DR, et al: A multivariate analysis of 416 patients with glioblastoma multiforme: prognosis, extent of resection, and survival. *J Neurosurg* 2001; 95:190-98.
15. Albert FK, Forsting M, Sartor K, et al: Early postoperative magnetic resonance imaging after resection of malignant glioma: objective evaluation of residual tumor and its influence on regrowth and prognosis. *Neurosurgery* 1994; 34:45 - 60.
16. Barker FG, Prados MD, Chang SM et al. Radiation response and survival time in patients with glioblastoma multiforme. *J Neurosurg* 1996; 84:442 - 48.
17. Vecht CJ, Avezaat CJ, van Putten WL, et al: The influence of the extent of surgery on the neurological function and survival in malignant glioma. A retrospective analysis in 243 patients. *J Neurol Neurosurg Psychiatry* 1990; 53:466 - 71.
18. Vuorinen V, Hinkka S, Farkkila M, Jaaskelainen J: Debulking or biopsy of malignant glioma in elderly people: a randomised study. *Acta Neurochir (Wien)* 2003; 145:5-10.
19. Majos A, Tybor K, Stefanczyk L, Goraj B. Cortical mapping by functional magnetic resonance imaging in patients with brain tumors. *Eur Radiol* 2005; 15:1148-58.
20. Kamada K., Sawamura Y., Takeuchi F., et al: Functional identification of the primary motor area by corticospinal tractography. *Neurosurgery* 2005; 56(Suppl ONS 1):ONS-98-ONS-109
21. Wu J.-S., Mao Y., Zhou W.-J., et al: Clinical evaluation and follow-up outcome of diffusion tensor imaging-based functional neuronavigation: a prospective, controlled study in patients with gliomas involving pyramidal tracts. *Neurosurgery* 2007; 61(5):935-948. (discussion 948-49)
22. Nimsky C, Ganslandt O, Hastreiter P et al: Preoperative and intraoperative diffusion tensor imaging based fibre tracking in glioma surgery. *Neurosurgery* 2005; 56(1):130-38,
23. Kuhnt D, Bauer M, Becker A, et al: Intraoperative visualization of fibre tracking based reconstruction of language pathways in glioma surgery. *Neurosurgery* 2012; 70(4):911-20,
24. Knauth M., Wirtz C.R., Tronnier V.M., et al: Intraoperative MR imaging increases the extent of tumor resection in patients with high-grade gliomas. *AJNR Am J neuroradiol* 1999; 20:1642-46.

(Dr Rana Patir, Director and Head, Department of Neurosurgery, Fortis Memorial Hospital, Gurgaon)

PERSPECTIVE

IMPACT OF ADVANCES IN RADIATION ONCOLOGY IN THE TREATMENT OF CNS TUMORS

Since its inception over a century ago, the field of radiotherapy has undergone an amazing series of developments. The most important of these developments has been the paradigm of fractionated dose delivery, technologic advances in X-ray production and delivery, improvement in imaging and computer-based treatment planning, and evolving models that predict how cancers behave and how they should be approached therapeutically. In addition, challenges in treatment planning and radiation delivery, such as problems with setup error and organ movement, have begun to be systematically addressed, ushering in an era of so-called 4-dimensional radiotherapy.

Radiation therapy is a major component of the treatment of many primary and metastatic brain tumors. Standard therapy for glioblastoma multiforme and other primary malignant astrocytomas consists of radiotherapy after the fullest possible surgical resection has been performed.

Benefit of imaging

Newer advances, including Contrast-enhanced CT, Magnetic resonance imaging, magnetic resonance spectroscopy, and positron emission tomography, provide unique insights into neuro-oncology, which are contributing to the better management of patients with brain tumors. The next decade will witness further sophistication of these techniques, with data available from larger studies.

Intensity-Modulated Radiotherapy

The inception of IMRT brought with it great optimism with regard to brain tumors because the radiation dose conformality available with IMRT is unparalleled. It also allows for reduction in the maximum doses to organs at risk, such as the brainstem, optic chiasm, lens, optic nerves, and cerebral cortex, while achieving comparable target coverage in treatment of the central nervous system. In the pediatric population with medulloblastoma, treatment with IMRT can achieve a lower rate of hearing loss despite usage of higher doses of cisplatin. Figure 1 shows the IMRT planning for a 10-year boy who presented as high risk case and underwent radiotherapy in supine position.

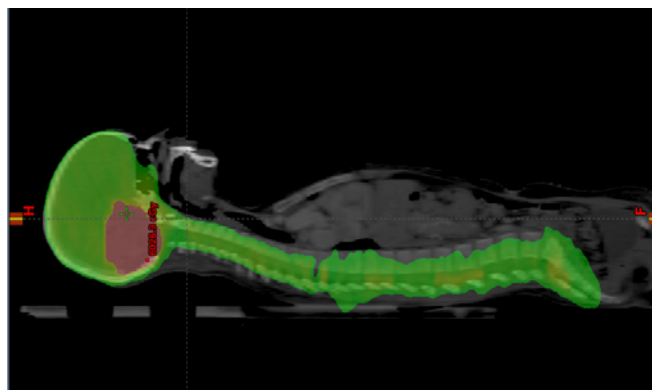


Fig 1: IMRT Planning for a case of medulloblastoma

In glioblastoma patients, IMRT shows reduction in normal toxicity but dose escalation, regardless of method, does not appear to lead to improvement in patient outcomes.

Stereotactic Radio Surgery/Stereotactic Radiation Therapy

Stereotactic radio surgery (SRS) and stereotactic radiation therapy (SRT) are forms of hypo fractionated high-precision, radiotherapy delivery. They are characterized by (1) reproducible immobilization of the target; (2) measures to account for tumor motion during imaging, treatment planning, and radiation delivery; (3) use of dose distributions tightly covering the tumor, with rapid dose fall-off in surrounding normal tissues to reduce toxicity; and (4), most importantly, the use of large fraction radiation doses (SRS).

In the past stereotactic radiation therapy, such as with the Gamma Knife was used for brain tumors. The patient was immobilized in a bolted head frame and the radiation was applied to the tumor with multiple, sometimes as many as 200, separate narrow beams that all converged on the tumor. Newer devices allow stereotactic treatment without using a frame under image guidance but the concept still remains same, i.e. cancer is treated from multiple angles such that the tumor receives a large dose but the normal tissues receive much less. Clinical studies for recurrent glioblastoma revealed median survival of 8.5 months for SRS and 7.4 months for fractionated stereotactic radiotherapy.

IGRT

By incorporating real-time image guidance within intensity modulated radiation therapy (IMRT), IGRT allows radiation oncologists to adjust the radiation beams so that radiation is delivered with even more precision. With cone-beam CT, we can locate and track

the brain tumor at the time of treatment, and conform the radiation to the brain tumor. The development of frameless image-guided radiation delivery systems greatly extend the flexibility of radio surgical treatments. Without a frame, there are more choices in beam angle, which makes hypofractionated stereotactic radiotherapy easier. The CyberKnife (Accuray Inc., Sunnyvale, CA) and Novalis (BrainLAB AG, Heimstetten, Germany) linear accelerator systems show adequate precision and reliability for intracranial radio surgery, using either frame-based or frameless image-guided methods.

Particle Radiation Therapy

Proton Therapy

Protons, which are generated by a cyclotron, deposit their energy at the end of the proton's beam path (the Bragg peak). Thus, practically no radiation dose is deposited in the tissue that lies beyond the Bragg peak on the beam axis as compared with the exponential decrease of a non-charged particle-delivered radiation dose with depth in tissue. This property is specially valuable when treating brain tumors close to other critical organs and parts of the nervous system. The brain tumors most appropriate for proton therapy include:

- Gliomas (astrocytomas)
- Ependymomas
- Medulloblastomas
- Pineoblastomas
- Supratentorial PNET
- Germ cell tumors
- Pituitary gland tumors
- Almost all pediatric brain tumors

Arteriovenous malformations (AVMs) of the brain can also be treated using protons.

Carbon Ion Therapy

Heavy ion therapy is a novel technique of high precision external radiotherapy. It yields a better perspective for tumor cure of radio-resistant tumors. Heavy ion therapy is not a general solution for all types of tumors. As compared to conventional radiotherapy, heavy ion radiotherapy has the following advantages:

- Higher tumor dose and improved sparing of normal tissue in the entrance channel.
- More precise concentration of the dose in the target volume with steeper gradients to the normal tissue.
- Higher radiobiological effectiveness for tumors which are radio-resistant during conventional therapy.

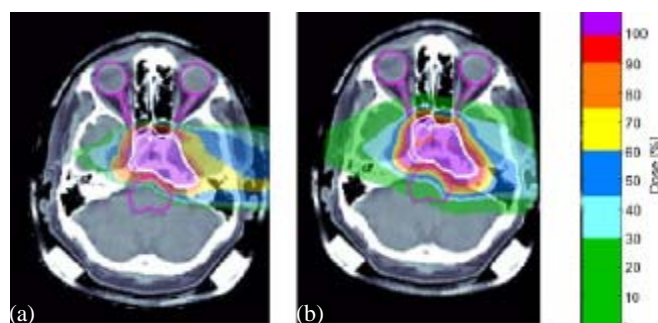


Fig 2: Comparison between carbonion (a) and proton (b)

The results of combined therapy using 50 Gy of X-ray and 24.8 GyE of carbon ion beam showed improved survival rate for malignant gliomas. The efficacy of carbon ion radiation therapy needs confirmation in controlled clinical trials with large patient numbers comparing carbon ion RT with photon IMRT and proton RT, taking into account toxicity and quality of life.

Boron Neutron Capture Therapy

Boron neutron capture therapy (BNCT) is a promising therapeutic modality for the treatment of malignant brain tumors. It is 2-step technique in which compounds labeled with boron are injected into the patient and depending on the tumor entity; the injected compounds are more or less selectively enriched in tumor cells. Then, patients are irradiated with low-energy neutrons from a nuclear reactor which release alpha particles. They have a limited range of 5 to 9 μ m, and so the therapeutic irradiation is practically limited to the cells with the high boron concentration.

Small phase I/II trials for newly diagnosed glioblastoma have overall median survivals in the range of 13 to 20.7 months. Toxicities are typically acute and related to a temporal increase in intracranial pressure. However, the challenge remains for systematic improvement of selective boron delivery.

Brachytherapy

Implantation of irradiation sources (brachytherapy) has been used for intrinsic brain tumors and metastases for more than four decades in numerous patients. The majority of studies reported about the application of high-dose rate (HDR) iodine-125 implants (40-70 cGy/h) for high-grade gliomas, including two prospective randomized trials, which compared standard treatment regimens with/without BT. This approach, however, was associated with high incidence of radiation induced adverse effects requiring repeated surgery and failed to prove any significant oncological benefit as compared to

standard treatment regimens. Another approach using SBT was the application of low-dose rate (LDR) implants (3-8 cGy/h) for slow growing low-grade gliomas or brain metastases which demonstrated in several very recent publications to be associated with only little permanent deficits and almost an absence of radiation induced necrosis.

GliaSite Radiation Therapy System

Intracavitary balloon catheter brain brachytherapy is a recent approach to localized radiation therapy delivered with an inflatable balloon catheter filled with radioactive ¹²⁵I liquid through a subcutaneous reservoir. It adheres to the walls of the resection cavity, allowing the tumor bed to receive high dose of radiation, while sparing the surrounding brain tissue.

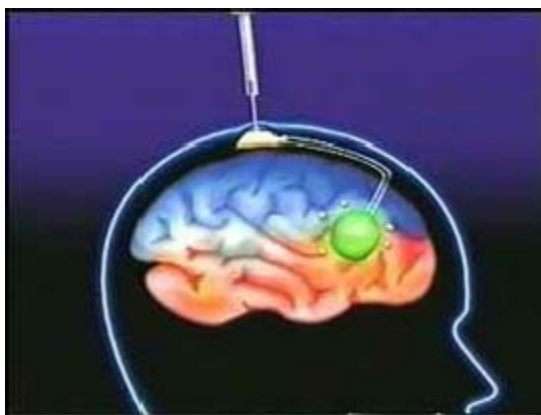


Fig 3: GliaSite in Malignant glioma

A New Approaches to Brain Tumor Therapy Central Nervous System Consortium study investigating GliaSite in the treatment of recurrent malignant gliomas determined that the GliaSite system delivers brachytherapy safely and efficiently. Patients in the New Approaches to Brain Tumor Therapy study received 4000 to 6000 cGy to the target volume via the GliaSite system, and a median survival of 12.7 months was observed in this population with recurrent disease.

What is clear is that a megatrend in cancer treatment is a steady, indeed rapid, advance in the ability to deliver radiation therapy in a more effective, safer manner, often in much less time than in the past. Radiotherapy, including BRT may hold more promise if biologic mechanisms of radiation can be better understood and biologic modifications could be added in clinical trials.

(Dr Ritu Bhutani, Consultant; Dr Sheh Rawat, Sr Consultant; Dr Gourav Gupta, Sr Resident; Dr Rashmi Singh, Sr Resident; Dr Parveen Ahlawat, DNB Student, Dept of Radiation Oncology)

CANCER CONTROL

Brain Cancer among Farm Workers

A study conducted at National School of Public Health, Rio de Janeiro, Brazil, has shown increased risk of brain cancer among agricultural farm workers. In this case-control study 2040 individuals were defined as having brain cancer as the underlying cause of death based on death certificates of males, (18 years or older), who died between 1996 and 2005. For each case two controls (n=4140) were randomly selected, matched for age group and region of residence. Besides the descriptive analysis, crude and adjusted odds ratios and mortality odds ratio were calculated. Agricultural workers showed higher brain cancer mortality risk estimates when compared with non-farm workers. In addition, the association was higher among white patients, with higher education, and residence in an agricultural region. This study suggests an association between agricultural work and brain cancer mortality and also suggests that pesticide exposure may play a role in such risk.

(*Int J Hyg Environ Health*, Sep 2012)

Parity, Age at First Birth, and Risk of Brain Cancer

Researchers from Kaohsiung Medical University, Taiwan have shown that parity and early age at first birth may play a role in the risk of brain cancer. The study was conducted on 1,292,462 women who had a first and singleton child birth from 1978-87. Each individual woman was tracked from the time of their first childbirth to 2009, and their vital status was ascertained by mortality database. There were 316 brain cancer deaths during 34,980,246 person-years of follow-up. The mortality rate of brain cancer was 0.90 cases per 100,000 person-years. The adjusted Hazard Ratio (HR) was higher for women who gave birth between 21 & 25, and for women who gave birth after 25 years of age, when compared with women who gave birth less than 20 years. A trend of increasing risk of brain cancer was seen with increasing age at first birth. The adjusted HR was higher for women who had given birth to only one child compared to women who had 2 children, and women with 3 or more births. There was a significant decreasing trend in the HRs of brain cancer with increasing parity. This study provides evidence that parity and early age at first birth may confer a protective effect on the risk of death from brain cancer.

(*BMC Public Health*, Oct 9, 2012)

NEW TECHNOLOGIES

Drug for Rare Pediatric Brain Tumor

The US Food and Drug Administration has approved Afinitor Disperz, a new pediatric dosage form of anti-cancer drug Afinitor to treat subependymal giant cell astrocytoma, a rare brain tumor. The drug has been recommended to treat patients with age of one year and older with tuberous sclerosis simplex (TSC) whose tumor cannot be surgically removed. The TSC is a rare genetic disease which causes tumors to grow in brain and other vital organs. The appropriate dosage forms, like Afinitor Disperz, help to ensure the safe and effective use of oncology drug in children. The drug is available in smaller dose increments than the adult dosage form and gets easily dissolved in a small volume of water. This makes drug administration easy in the patients who are unable to swallow the whole tablet. The active ingredient in drug works by blocking the uncontrolled activity of a protein called mTOR kinase. The most common side effects of the drug observed were mouth ulcers and respiratory tract infections. The drug is classified as an orphan drug because it is intended to treat a rare disease condition.

(US Food and Drug Administration, Aug 29, 2012)

Laser Technology to Fight Brain Tumor

A team of investigators at the University of Tennessee have developed a superfast laser procedure that could serve as a non-invasive treatment of cancer, especially when the disease is located in the brain. The technology works by seeking and destroying cancerous tumors. The technology uses a femtosecond laser, that means it pulses at speeds of one-quadrillionth of a second. Such higher speed makes it possible to focus on a particular region and acutely locate the tumor. After the cancerous area is targeted, only the laser radiation needs to be turned up to irradiate the tumor. The technique has the competence to be more precise than existing methods and the treatment may be administered as an outpatient procedure. The imaging mechanism can non-invasively permeate thin layers of bone, such as skull. Furthermore, due to its precision, there is less chance of collateral damage of healthy brain tissue. The method may also overcome the limitations of photodynamic therapy that has limited application and surgery which may not be a choice if the whole carcinogenic tissue cannot be removed.

(The University of Tennessee, July 23, 2012)

New Surgical Probe for Brain Tumors

Researchers at the Norris Cotton Cancer Center and the Thayer School of Engineering at Dartmouth College, Hanover, have developed a probe which may be used to differentiate cancerous tissue from normal during surgery. The primary brain tumors look like brain tissue and can be differentiated only if seen under a particular kind of light. To improve ability to discriminate between tumor cells and healthy tissue during surgery, the patients are given an oral dose of chemical 5-aminolevulinic acid (ALA). An enzyme metabolizes ALA and produces the fluorescent protein PpIX. Tumor cells have a higher metabolic rate than normal cells, so can accumulate more PpIX and thereby fluoresce on exposure to blue light. The new surgical probe combines violet-blue and white light to simultaneously analyze the concentration of PpIX and four other biomarkers: PpIX breakdown products, oxygen saturation, hemoglobin concentration and irregularity of cell shape and size. The probe reads how the light travels after hitting tissue and sends this information to computer, runs it through an algorithm and shows the cancerous tissue. Another advantage of the method is the capability to highlight the low-grade tumor in tissue. The probe introduces a promising method to help surgeons to remove the tumor while preserving intact adjacently healthy tissue.

(Science Daily, July 24, 2012)

Spectroscopic 'Fingerprints' to Diagnose Brain Tumors

Researchers at Lancaster University have shown that infrared (IR) and Raman spectroscopy, coupled with statistical analysis can be used to differentiate diseased brain tissue from healthy tissue. The Raman spectroscopy-driven 'fingerprinting' technique, based on its biochemical-cell fingerprint, yields accurate results in seconds. The method is also able to identify whether the tumor originated in brain or was secondary cancer arising from an unknown primary site. This would help to recognize previously undetected cancer elsewhere in the body and thus improve patient outcomes. The current method may be combined with conventional methods, such as immunohistochemistry, to detect and grade brain tumors to allow for more accurate planning and execution of surgery/ radiation therapy which offers more potential for individualized treatment. The current study indicates that IR and/or Raman spectroscopy have the potential to provide a novel diagnostic approach in the accurate diagnosis of brain tumors and may also be used in intra-operative diagnosis.

(Anal Methods, Sep 7, 2012)

CLINICAL TRIALS

Bevacizumab and Irinotecan in Primary Brain Tumors

Researchers from Rigshospitalet, Denmark, performed a prospective phase II trial to see the efficacy of bevacizumab and irinotecan in patients with primary brain tumors and progression after standard therapy. A total of 85 patients were recruited in the study and given intravenous bevacizumab 10mg/kg and irinotecan 125/340 mg/m² every 14 days. Primary endpoints were progression free survival (PFS) and response rate. Evaluation was carried out every eight weeks using magnetic resonance imaging and Macdonald response criteria. Of these patients, 32 had glioblastoma multiforme (GBM), 33 had glioma WHO gr.III, 12 WHO gr. II glioma and 8 patients were with different histologies. Results revealed that overall response rate (ORR) for GBM was 25% and 59% achieved stable disease (SD) and median PFS was 5.2 months. For grade III gliomas ORR was 21% and 45% had SD and median PFS was 3.7 months. Majority of the patients achieve at least disease stabilization. This trial showed that combination of bevacizumab and irinotecan is well tolerated and moderately efficacious in GBM and WHO gr. III gliomas

(*Acta Oncol*, July 2012)

Dasatinib Plus Erlotinib in Recurrent Malignant Glioma

The outcome for the patients with metastatic medulloblastoma (MB) is poor. A phase I/II trial was done at Children's Hospital of Pittsburgh, to estimate the feasibility of administering carboplatin as a radiosensitizer during craniospinal radiation therapy (CSRT) to patients (n=57) with high-risk. All the patients underwent surgical debulking followed by 36 Gy CSRT. During CSRT, patients received weekly vincristine as well as carboplatin doses ranging from 30 mg/m²/dose x 15 to 45 mg/m²/dose x 30, given 1-4 hours prior to each RT fraction. Six weeks after completing chemoradiotherapy, patients received six courses of monthly CPM (2 gm/m²) and VCR. Four-year overall survival (OS) and event-free survival (EFS) for the entire group is 81 ± 5% and 66 ± 6%. Thrombocytopenia was dose limiting and 35 mg/m² was selected as the maximum tolerated carboplatin dose. The overall results showed that the use of daily carboplatin as a radiosensitizer appears to be a promising strategy for patients with metastatic MB.

(*J Clin Oncol*, July 2012)

Treatment Options for Elderly Patients with GBM

A randomised phase III trial was conducted at Linköping University, Sweden, to assess the optimum palliative treatment in patients age 60 years and older with glioblastoma (GBM). Total 342 patients with newly diagnosed GBM were recruited, randomized and given temozolomide (TMZ) [200 mg/m² on days 1-5 of every 28 days for up to six cycles], hypofractionated radiotherapy (HypoRT) (34.0 Gy in 3.4 Gy fractions over 2 weeks), or standard radiotherapy (RT) (60.0 Gy in 2.0 Gy fractions over 6 weeks). From total 342 patients, 291 were randomised across three treatment groups (TMZ n=93, hypoRT n=98, standard RT n=100) and 51 of them were randomised across only two groups (TMZ n=26, hypoRT n=25). Outcome of the study showed similar overall survival (OS) for the patients receiving TMZ or hypoRT (8.4 months [n=119] vs 7.4 months [n=123]) but median OS was significantly longer with TMZ. For age older than 70 years, survival was better with TMZ and with hypoRT than with standard RT. Through the study it was confirmed that both TMZ and hypoRT should be considered as standard treatment options in elderly patients with GBM.

(*Lancet Oncol*, Sep 2012)

Verubulin & Carboplatin in Relapsed GBM

A phase I trial was conducted at the Huntsman Cancer Institute, University of Utah to determine the safety and tolerability of verubulin in combination with carboplatin in patients (n=19) with relapsed glioblastoma multiforme (GBM), who had received prior treatment with surgery, radiotherapy, temozolomide and had either residual or recurrent disease. Three pre-selected doses of verubulin were tested: 2.1, 2.7, and 3.3 mg/m² and it was given every second week of a 6-week cycle in the 2.1 mg/m² cohort or weekly for 3 weeks of a 4-week cycle in subsequent cohorts. Carboplatin was administered every 2 weeks for the 2.1 mg/m² cohort or on day 1 of each 4-week cycle in subsequent cohorts. Of these patients, 2 achieved partial response, 1 remained progression free and 5 patients had stable disease. Adverse events were seen in 4 patients, including hypesthesia, cerebral ischemia and anemia. Through this study, it was concluded that the combination of verubulin at the previously determined single-agent maximum tolerated dose of 3.3 mg/m² with carboplatin in patients with recurrent/refractory GBM is safe and well tolerated

(*J Neurooncol*, Nov 2012)

GLOBE SCAN

Working Memory and Facial Expression

Patients with brain tumors may have cognitive dysfunctions, including memory deterioration, such as working memory, that affect quality of life. This study explored the presence of defects in working memory and the identification of facial expressions in patients with left frontal glioma. This case-control study recruited 11 matched pairs of patients and healthy control subjects from March through December 2011. The psychological tests contained tests that estimated verbal/visual-spatial working memory, executive function, and the identification of facial expressions. According to the paired samples analysis, there were no differences in the anxiety and depression scores or in the intelligence quotients between the 2 groups. Patients with left frontal glioma had deficits in verbal working memory and the ability to identify anger. These may have resulted from damage to functional frontal cortex regions, in which roles in these 2 capabilities have not been confirmed. However, verbal working memory performance might be affected by emotional and tumor-related factors.

(China: *Neuro Oncol*, Sep 14, 2012)

Integrins and p53 Pathways

Glioblastoma is the most common malignant primary brain tumor. Surgical resection, postoperative radiotherapy plus concomitant and adjuvant chemotherapy with temozolomide (TMZ) is the standard of care for newly diagnosed glioblastoma. In the past decade, efforts were made to decipher genomic and core pathway alterations to identify clinically relevant glioblastoma subtypes. Based on these studies and more academic explorations, new potential therapeutic targets were found and several targeting agents were developed. Such molecules should hopefully overcome the resistance of glioblastoma to the current therapy. One of the hallmarks of glioblastoma subtypes was the enrichment of extracellular matrix/invasion-related genes. Integrins, which are cell adhesion molecules important in glioma cell migration/invasion and angiogenesis, were one of those genes. Integrins seem to be pertinent therapeutic targets and antagonists recently reached the clinic. Although the p53 pathway appears often altered in glioblastoma, conflicting results can be found in the

literature about the clinically relevant impact of the p53 status in the resistance to TMZ.

(France: *Front Oncol*, Oct 31, 2012)

Epilepsy in the End-of-Life Phase

Epilepsy is common in patients with brain tumors. Patients presenting seizures as the first sign of a malignant glioma are at increased risk of recurrent seizures despite treatment with antiepileptic drugs. However, little is known about the incidence of epilepsy in the last stage of disease and in the end-of-life phase of brain tumor patients. A total of 157 patients were available for analysis. Of these patients, 58 (36.9 %) presented seizures in the last month before death. The risk of seizures in the end-of-life phase is higher in patients presenting previous history of epilepsy, particularly in patients with late-onset epilepsy. Out of the 58 patients presenting seizures in the last month of life, 86.2 % had seizures previously and 13.8 % were seizure-free. Most patients may encounter swallowing difficulties in taking anticonvulsants orally due to dysphagia and disturbances of consciousness, thus anticonvulsant treatment needs to be modified in advance.

(Italy: *J Neurooncol*, Oct 20, 2012)

Risk of Brain Tumors

People who carry a “G” instead of an “A” at a specific spot in their genetic code have roughly a six-fold higher risk of developing certain types of brain tumors. This could help researchers identify people at risk of developing certain subtypes of gliomas which account for about 20 percent of new brain cancers diagnosed annually in the US and may lead to better surveillance, diagnosis and treatment. A few years ago, researchers began hunting for regions of the genome that might be associated with the development of gliomas. They observed a portion of chromosome 8 that contained single nucleotide polymorphisms or “SNPs” associated with brain tumors. One — the SNP called rs55705857 — confers a relative risk approaching that seen with BRCA1, the breast cancer gene. This region was only found through the most laborious method used by the researchers, next generation sequencing, suggesting that experimental and mathematical shortcuts may miss such rare, highly potent gene variants. They found that having the “G” guanine version of this SNP — rather than the more common “A” adenine version — was strongly associated with slower growing gliomas.

(USA: *Nature Genetics*, Aug 26, 2012)

INFOCUS

METHYL GUANINE METHYL TRANSFERASE IN CNS TUMORS

DNA is the most important molecule supporting life that ensures structural and functional integrity of a cell. DNA must remain unaltered through the life of a cell and alterations in DNA called mutations or rearrangement can inexorably push the cell to its death or more ominously towards cancerous transformation. Such sinister being the implications of DNA alterations, its immediate repair to restore normal structure is of paramount importance and nature has built in a near fool proof mechanism of DNA repair albeit with some slippages occasionally with its deleterious consequences.

The mechanisms of DNA repair can be divided into two broad categories:

1. Reversal of the chemical reaction responsible for DNA damage
2. Removal followed by replacement of the damaged bases by newly synthesized correct bases/nucleotides.

The latter of the two is the dominant process and one of greater importance, however, in the present context it is the former that interest us and is discussed in some detail below.

UV light causes DNA damage by formation of pyrimidine dimers, in which adjacent pyrimidines on the same strand of DNA are joined by the formation of a cyclobutane ring resulting from saturation of the double bonds between carbons 5 and 6. The formation of such dimers deforms the structure of the DNA chain and blocks transcription or replication past the site of damage, so their repair is closely correlated with the ability of cells to survive UV irradiation. One mechanism of repairing UV-induced pyrimidine dimers is direct reversal of the dimerization reaction. The process is called photoreactivation because energy derived from visible light is utilized to break the cyclobutane ring structure. The original pyrimidine bases remain in DNA, now restored to their normal state. As might be expected from the fact that solar UV irradiation is a major source of DNA damage for diverse cell types, the repair of pyrimidine dimers by photoreactivation is common to a variety of prokaryotic and eukaryotic cells, including *E. coli*, yeasts, and some species of plants and animals.

Curiously, however, photoreactivation is not universal; many species (including humans) lack this mechanism of DNA repair.

Another form of direct repair deals with damage resulting from the reaction between alkylating agents and DNA. Alkylating agents are reactive compounds that can transfer methyl or ethyl groups to a DNA base, thereby chemically modifying the base. Particularly important type of damage is methylation of the O⁶ position of guanine, because the product, O⁶-methylguanine, forms complementary base pairs with thymine instead of cytosine. This lesion can be repaired by an enzyme called “O⁶-methylguanine methyltransferase” (MGMT) that transfers the methyl group from O⁶-methylguanine to a cysteine residue in its active site. The potentially mutagenic chemical modification is thus removed, and the original guanine is restored. This direct repair reaction is widespread in both prokaryotes and eukaryotes, including humans and is carried out by enzyme MGMT (Fig 1).

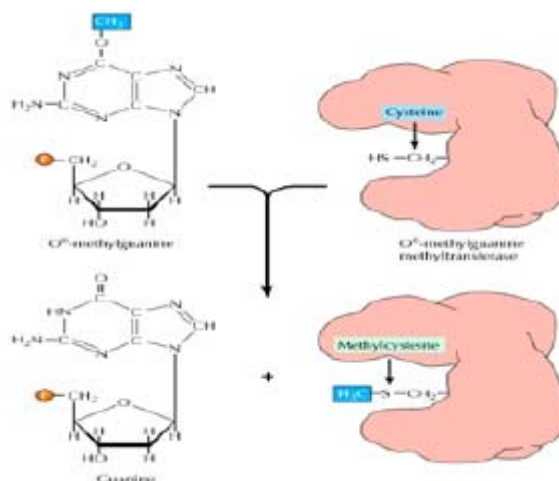


Fig 1: The methyl group has been taken up by MGMT. It is however, not reconstituted and in that sense different from a true enzyme.

MGMT & Glioblastoma (GBM)

With this background, let us now see the role of treatment of gliomas with Temozolomide and the cooperation of the DNA-Repair Gene MGMT.

Temozolomide (TMZ) is the only anticancer drug that has been shown in a phase III study to improve survival in GBM when administered with concomitant radiotherapy. TMZ is an oral alkylating agent that leads to cell death by alkylation of the O⁶ position of guanine and subsequent disturbance of DNA replication. Those brain tumors which have Epigenetic silencing of O⁶-

methylguanine-DNA-methyltransferase (MGMT) by promoter methylation respond to Temozolomide, however, those bereft of this epigenetic silencing of MGMT respond poorly. Let us deal in subsequent paragraphs with see the mode of action of TMZ and the synergistic effect of MGMT silencing.

Orally administered TMZ is converted into 5-(3-methyltriazene-1-yl)imidazole-4-carboximide (MTIC) in water/blood with little or no enzymatic component. MTIC is broken down to methyl diazonium cation and 5-aminoimidazole-4-carboxamide (AIC). AIC is excreted via the kidneys and methyl diazonium cations deliver methyl groups to DNA. These methyl groups are transferred to the 6th position oxygen atoms of guanine and O⁶-methylguanines are formed. O⁶-methylguanine mispairs with thymine instead of cytosine during DNA replication. The O⁶-methylguanine:thymine mispair can be recognized by the post-replication mismatch repair system, which removes a daughter strand along with the thymine, leaving the O⁶-methylguanine to again pair with thymine during gap filling [Fig 1]. If replication of the gapped structure occurs, double-strand breaks can form. Unless repaired by the recombination repair pathways, they result in cell death [Fig 2]. Because this cytotoxicity is replication-dependent, methylating agents, including TMZ, are more effective on tumor cells than on quiescent cells

Temozolomide (TMZ) is an anticancer drug that adds methyl adducts (M) to DNA, which eventually

leads to apoptosis. Tumor cells can resist killing by expressing wild-type methylguanine methyltransferase (WT-MGMT), a DNA-repair protein that excises toxic methyl lesions from the O⁶ position of guanine residues. Haematopoietic stem cells produce very low levels of MGMT and are therefore killed by TMZ (Fig3). Treatment of cells with O⁶-benzylguanine (B or 6-BG) can overcome WT-MGMT-mediated resistance. This drug binds directly to MGMT, inactivating its ability to repair DNA. Hence 6 BG can extrinsically induce silencing of O⁶-methylguanine-DNA-methyltransferase making Temozolomide effective in those tumors which do not have intrinsic epigenetic silencing of MGMT.

A significant disadvantage of treating patients with 6-BG is that it makes haematopoietic cells even more sensitive to TMZ, and the resulting bone-marrow toxicity becomes dose limiting (Fig 3). Bone-marrow cell protection can be achieved by transducing haematopoietic stem cells with a vector that expresses a P140K mutant MGMT cDNA (P140K). This MGMT variant is resistant to 6-BG-induced inactivation, but retains significant DNA-repair activity. Treating patients with TMZ and 6-BG, when their stem cells express the P140K vector, might allow for tumor-cell killing with concomitant bone-marrow protection.

There is pressing need for molecular tests that assist in the identification and monitoring of the most effective treatment for each individual cancer patient. This is especially true with cancer therapeutics that relies on

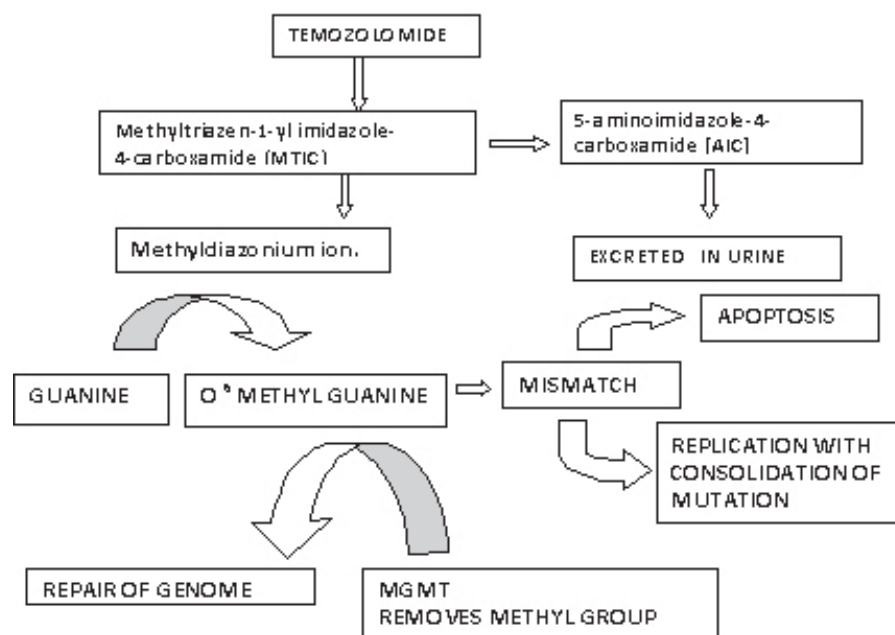


Fig 2: Mechanism of action of temozolomide . MGMT by removal of methyl group repairs the genome thereby preventing apoptosis. Silencing of MGMT does not allow the genomic repair and pushes the cell to its demise through apoptosis.

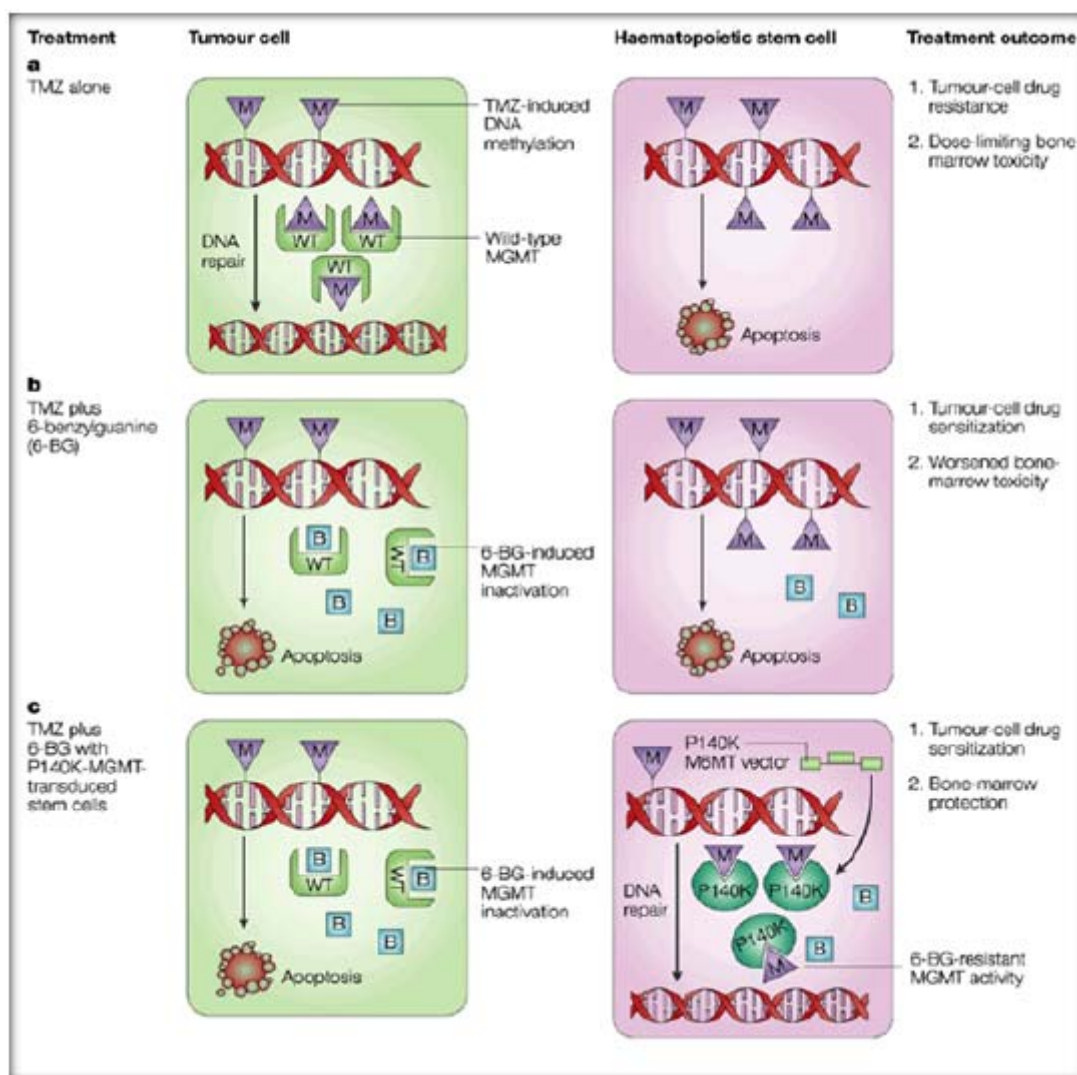


Fig 3: Showing mechanism of action of TMZ with its synergistic effect in combination with 6-BG and there bone marrow toxicity.

inducing DNA damage in the tumor. MGMT protein and mRNA levels in tumor tissues can be evaluated by immunohistochemistry, and reverse transcription-PCR (RT-PCR)/real-time RT-PCR, respectively. The activity of MGMT is measurable by an enzyme assay. The methylation status of the MGMT gene has been assessed with methylation-specific PCR using bisulfite-modified DNA samples. For diagnostic purposes, the methylation-specific PCR is of advantage compared with the measurement of MGMT protein activity or mRNA level because tissue contamination of non-neoplastic cells does not interfere with the detection of genomic methylation in tumor cells. Additionally, it is difficult to apply immunohistochemistry to assess MGMT expression for diagnostic purposes as the immunostaining procedures and antibodies might differ between different laboratories.

Furthermore, as revealed by qualitative analysis studies, the correlation between the methylation status of

the MGMT promoter and the relative MGMT expression level (either positive promoter methylation and low expression or negative promoter methylation and high expression) has been found statistically significant, indicating that patients with glioblastoma containing a methylated MGMT promoter benefited from temozolomide, whereas those who did not have a methylated MGMT promoter did not have such a benefit.

To conclude, Epigenetic silencing of O⁶-methylguanine-DNA-methyltransferase (MGMT) by promoter methylation is associated with improved survival in glioblastomas treated with alkylating agents. MGMT (AGT) activity is a critical determinant of alkylating agent sensitivity. MGMT inactivation may predict increased sensitivity to alkylating agents which are evaluated with promoter methylation assays.

(Dr Anurag Mehta, Director Lab Services; Dr Jatin S Gandhi, Specialist Lab Services, RGCI & RC)

THE PINK RIBBON MEET

Breast Cancer no longer rings a death bell. The paradise lost has been regained. October marks the birth of the pink ribbon and both October and the pink ribbon has ever since become synonymous with breast cancer. In an endeavour to care beyond cure and celebrate life beyond survival, Rajiv Gandhi Cancer Institute & Research Centre (RGCI & RC) organized “The Pink Ribbon Meet”, an annual symposium for breast cancer survivors as a tribute to all those pink fairies born out of labour of breast cancer on 22nd of October 2012 at India International Centre, New Delhi.

Dr. Kapil Kumar, Sr. Consultant & Chief, Breast, Thoracic & Soft Tissue Services, RGCI & RC, who had taken the initiative to organize the event welcomed the gathering. He said “Survivorship is a lifelong process. In its endeavour to care beyond cure, the Rajiv Gandhi Cancer Institute & Research Centre considers it a prime responsibility to create awareness about issues that challenge the survivors and to educate about methods to tackle them. Survivor symposiums lay the platform for interaction with cancer specialists, strengthen their bonds & enlighten them with knowledge applicable after treatment. Dietary measures to avoid weight gain, methods to combat lymphedema, Information on wigs and prostheses were dealt in a comprehensive manner”.

The event was inaugurated when the lamp was lit by Shri Rakesh Chopra (Chairman), Dr. A K Dewan (Medical Director) and Dr. Kapil Kumar. Dr. A K Dewan delivered the inaugural address and congratulated the survivors as “fighters”. Shri Rakesh Chopra launched a helpline (+91-11-4702 2007) in the hospital for breast cancer survivors on the occasion and hoped that the event would educate, entertain and empower survivors through the new jet of life.

Ms. Anita Kumari, Clinical Psychologist & Incharge of Breast Comprehensive Care Centre at RGCI & RC delivered a speech on issues pertaining to life beyond breast cancer. Then a presentation on exercise and posture to avoid lymphedema was given by Dr. Tarwinder Kaur, Physiotherapist, RGCI & RC. To Balance your energies Dietician Ms. Preeti Jain gave dietary tips to avoid obesity which is very much pertinent to breast cancer survivors.



Lamp Lighting Ceremony by (L to R) Dr A K Dewan, Shri R K Chopra and Dr Kapil Kumar



(L to R) Dr Kapil Kumar, Dr S A Rao, Dr D C Doval, Dr S K Sharma and Dr Jatin Gandhi

Ms. Indubala a cancer survivor who battled not once or twice but five times with breast cancer came up with her inspiring version of “when I met with breast cancer” which moved many of the audience to tears. Mrs. Sumana Basu & Mrs. Parmita both of them who had recent surgery for breast cancer volunteered to share their experience.

In a lighter vein the staff of RGCI & RC played a skit enacting the role of a young unwed newly diagnosed breast cancer patient in an educative manner. This was followed by an interactive “Ask the Expert’s Session”, where survivors clarified their queries with cancer specialists from the institute.

The breast cancer survivors signed off the event with their hands imprinted pink on the wall of appreciation.

(Dr S Veda Padma Priya, Consultant; Dr Ashish Goel, Consultant; Dr Kapil Kumar, Sr Consultant; Dept of Surgical Oncology)



**Rajiv Gandhi Cancer Institute
and Research Centre**

A Unit of Indraprastha Cancer Society
Registered under "Societies Registration Act 1860"

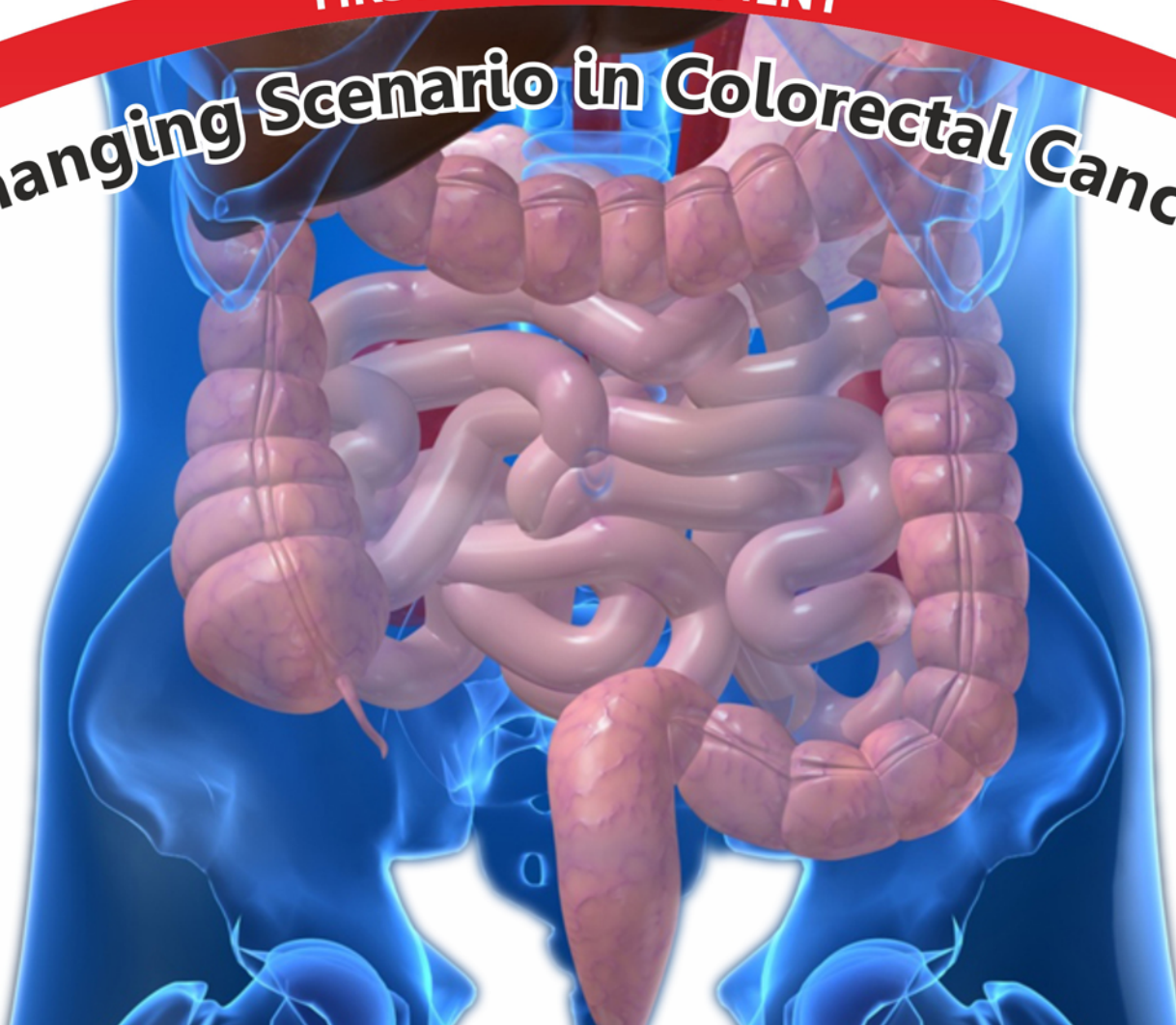12th ANNUAL INTERNATIONAL
CONFERENCE

RGCON
2013

15TH-17TH FEBRUARY

FIRST ANNOUNCEMENT

Changing Scenario in Colorectal Cancer



Dr. Sunil Kr. Gupta

Organizing Secretary, RGCON-2013

Sr. Consultant Medical Oncology, Rajiv Gandhi Cancer Institute & Research Centre
Mb: +91 98111 02971 • E-mail: rgcon2013@gmail.com • Website: www.rgcon2013.com