



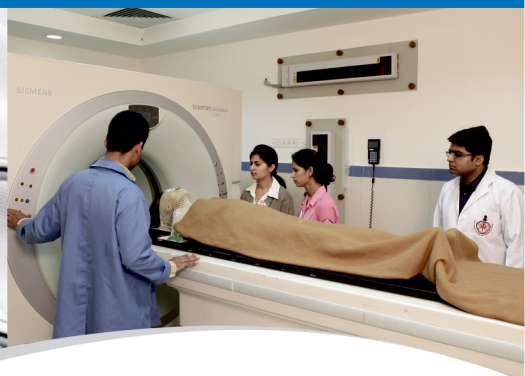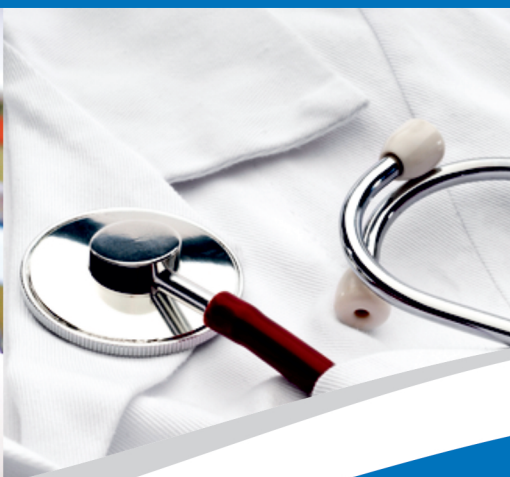# CANCER NEWS

ISSN 0973-9653

Vol 8

No 6

February 2015



Focus Area:  
**HEAD AND NECK CANCERS**



**Rajiv Gandhi Cancer Institute  
and Research Centre**

A Unit of Indraprastha Cancer Society  
Registered under "Societies Registration Act 1860"

***From the Desk of Director Research***

Head and neck cancers (including thyroid lesions) is the third most common malignancy seen in both the sexes across the globe but is the commonest malignancy encountered in Indian males. The actual burden of head and neck cancer in India is much greater than reflected through the existing literature and hence can be regarded as a 'tip of iceberg' situation. In India, head and neck cancers (HNCA) account for 20% cancers at all sites.

The anatomy of the Head and Neck is complex and is divided into sites and subsites. Tumors of each site have a unique epidemiology, anatomy, and natural history, and require different therapeutic approaches. The diagnosis of the head and neck cancer may at times be obvious on clinical presentation. In certain situations, however, this may be a dilemma for the clinician and the pathologist. In addition to establishing a pathologic diagnosis of squamous cell carcinoma of the head and neck, the work-up of these patients aims at delineating the exact extent of disease. This has important therapeutic and prognostic implications.

Head and neck cancer comprises a heterogeneous group of tumors, where optimal management requires a multidisciplinary approach. Surgery and radiotherapy are the major treatment modalities, sometimes combined with different chemotherapy schemes. Molecular profiling of head and neck tumors promise therapeutic advantage to the patients. Identification of clinically significant mutations can result in deeper insights that can guide therapeutic decisions. Multimodality treatment is often the only way to achieve improved function, quality of life, and survival, calling for a multidisciplinary team approach, particularly in view of the rapid advances being made in various fields.

The present issue of the Cancer News highlights the newer advances in the field of "Head & Neck Cancer" and features the regular articles, such as Special Feature, Guest Article, Perspective, Research & Development, New Technologies, Clinical Trials, Cancer Control, Globe Scan and In Focus. We are grateful to Dr. F. Christopher Holsinger, Chief, Head and Neck Surgery, Professor, Dept of Otolaryngology- Head and Neck Surgery Stanford University, CA, USA for the "Guest Article" and Dr. Gregory Weinstein Professor and Vice-Chair, Director, Division of Head and Neck Surgery, University of Pennsylvania, Philadelphia, PA, USA, for "Perspective", and Dr Urvashi Bahadur, Associate Director, Medical Genetics and Genomics, Strand Center for Genomics & Personalized Medicine, Bangalore for "In Focus".

Suggestions / comments from the readers are welcome.

*Dr D C Doval*

**CONTENTS**

- **Special Feature:** Multimodal Approach to Head & Neck Cancers [3-5]
- **Guest Article:** The Multidisciplinary Care of Oropharyngeal Carcinoma [6-8]
- **Watch Out:** Mugard Oral Mucoadhesive Hydrogel ; Methods of Treating Cancer using Inhibitors [8]
- **Perspective:** Why TransOral Robotic Surgery (TORS)? [9-10]
- **Research & Development:** miRNAs Expression and Local Recurrence; MAGEA3/6 as a Marker for Recurrence HNSCC; Novel Prognostic Model Oral Tongue Cancer; Nucleic Acid Amplification Assay in Head and Neck Cancer [11]
- **New Technologies:** Blood and Saliva Tests to Predict Recurrence; Lymphoseek to Determine Extent of Disease; Robotic Surgery for Inoperable Tumors [12]
- **Clinical Trials:** Afatinib for Metastatic Head and Neck Cancer; Benzydamine Oral Rinse Mucositis; Voice Quality after Treatment of Early Vocal Cord Cancer; Immunonutrition for Head & Neck Cancer [13]
- **Cancer Control:** Body Size and Risk of Head and Neck Cancer; Mediterranean Diet and the Risk of Oral and Pharyngeal Cancer; Serum Fatty Acids Beef Consumption and Salivary Gland Tumors [14]
- **Globe Scan:** Difference in Location of Oral Cancers; Diagnostic Value of CNB and FNAC; Pain Intensity to Predict Survival; F-18 FDG PET/CT in Head and Neck Cancers [15]
- **In Focus:** Next Generation Sequencing (NGS) Tests and Head and Neck Cancer [16-18]
- **Abstracts of Papers Published by RGCI & RC in 2014** [19]

**Research & Analysis Team**  
Research Department

Published by: **Rajiv Gandhi Cancer Institute & Research Centre**  
Sector - 5, Rohini, Delhi - 110 085, India

This publication aims at disseminating information on pertinent developments in its specific field of coverage. The information published does not, therefore, imply endorsement of any product/process/producer or technology by RGCI&RC.



**SPECIAL FEATURE****MULTIMODAL APPROACH TO HEAD & NECK CANCERS**

Multimodal treatment is often the only way to achieve improved functions, quality of life and survival, calling for a multidisciplinary team approach, particularly in view of the rapid advances being made in various fields. It is generally the only way to achieve satisfactory results and this requires clinicians of various fields to come together on a common platform. As science rapidly advances, it would be unwise to expect a single physician to keep abreast of the rapid pace of changes in all related fields of cancer treatment.

Multimodal team includes head and neck surgeon, radiation oncologist, medical oncologist, radiologist, pathologist, reconstructive surgeon, pain palliative therapist, nutritionist, speech therapist, nursing and social worker. Molecular biologists and nuclear medicine experts now also make part of the team. Tumor Board is a multidisciplinary group of doctors who meet on a regular basis to review cancer cases. Tumor Board meetings ensure that the cancer patients have access to the best current thinking about cancer management. Tumor Board is an accepted and established institution for multidisciplinary care of patients. RGCI&RC spends more than 6000 manhours per year in Tumor Board and MSC (Multi Specialty Clinic) discussions. Approximately 8% of the registered cancer patients are discussed in TB/MS.

Head and Neck Surgeon is often the torch bearer of the team. Surgery still remains the primary form of treatment of most head and neck cancers. Changes in surgical strategies are resulting in more varied treatments for the same stage of disease with more custom-designed operations for conservation of both form and function. Conservative surgeries are being performed for laryngeal and thyroid neoplasms. Conservation surgery in head and neck cancer requires twice as much experience and skill as in the case of so called radical surgery. T2 tumors of medial and posterior glottis may be resected endolaryngeally by Laser. It needs expertise in laser surgery.

Surgery may be the treatment of choice if the primary tumor can be excised with an appropriate margin of normal tissue and without causing major functional disorder. The choice of definitive local therapy must take into account mentioned below:

**Principals of Surgery****Surgery**

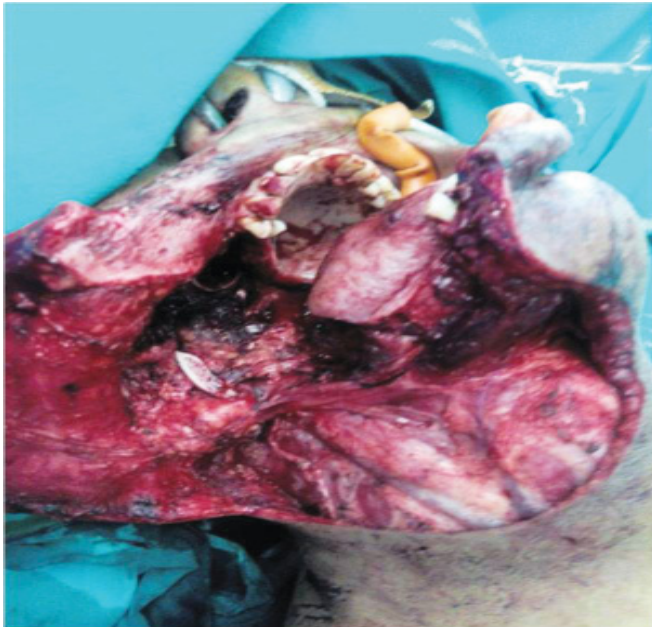- a) Likely functional outcome of treatment
- b) Resectability of tumor
- c) Performance status and associated co-morbidities
- d) Patient's preference

Treatment plans should be formulated by the multidisciplinary team in consultation with the patient. As part of this process, dental, speech and nutritional assessments are essential.

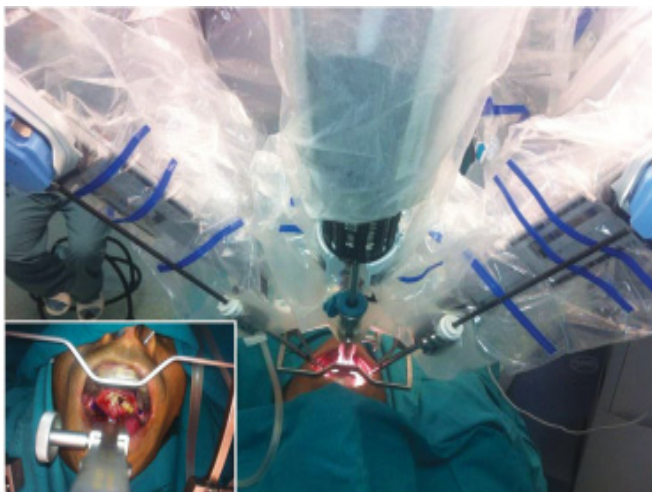
- a) Whenever possible, surgery for a primary head and neck cancer should preserve organ functions.



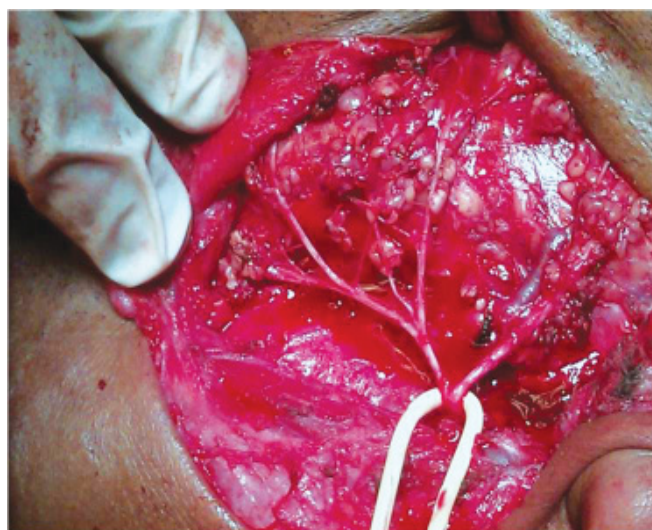
*Tumor Board meeting in Progress*



*Composite resection of buccal mucosa with infratemporal fossa clearance (Arrow depicting the infratemporal fossa)*



*Transoral robotic surgery (TORS) for oropharyngeal cancer*



*Branches of facial nerve in total parotidectomy*

- b) Whenever necessary, resection should be followed by reconstruction using the most appropriate techniques.
- c) Non-surgical treatment like radiotherapy (RT) with or without chemotherapy (CT) should be offered to patients if survival rates are comparable with that of surgical resection.
- d) Salvage surgery must be available if an organ preservation approach is to be pursued.
- e) Following resection, adjuvant RT & CT should be considered wherever indicated.

The main aim of surgery is to excise the area of malignancy ensuring that a margin of normal tissue surrounding the tumor is also removed and that radical excision is performed with curative intent.

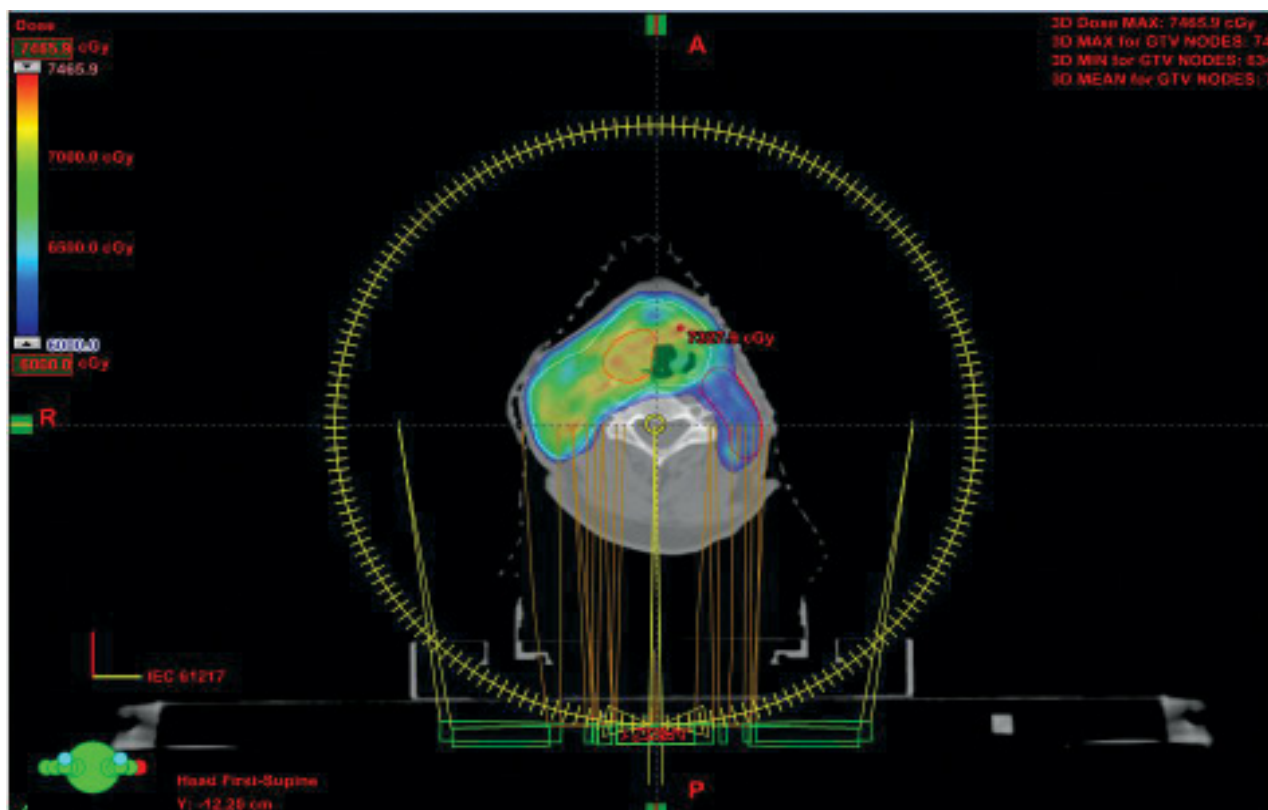
**Reconstructive Surgery:** is more demanding as patient demands restoration of form and function as close to normal as possible. More and more flaps are being designed based on a single perforator. The ability to raise chimeric flaps based on a single vascular pedicle allows for optimal usage of tissues in various planes without the need for additional anastomosis. Despite pertaining to form and function are still to be achieved these advances, certain goals. Prefabricated flaps have been used to replace mucosa with mucosa by employing tissue cultured mucosal sheets. The role of tissue engineering, especially in replacing mucosa, seems promising for the future.

**Imaging:** The ever increasing battalion of investigative tools in head and neck cancer has facilitated earlier diagnosis and efficient follow up. PET scan has been found to be useful in post radiation evaluation. Role of sentinel node biopsy in mucosal head and neck cancer has been evaluated.

**Radiation Therapy** is an integral arm in the treatment of head and neck cancer that has undergone significant advances. IMRT and IGRT represent new paradigms in treatment planning and dose delivery. There is significant sparing of critical structures and other normal tissues. IMRT is capable of delivering different doses to multiple targets, thereby providing a new opportunity for differential dose planning to increase dose selectively to specific image defined regions.

**Chemotherapy:** Role of CT in head and neck cancer is not clearly defined: CT has been used concurrently with radiation in advanced unresectable cases. Chemoradiation is also given when margins are involved by disease and nodes show extra capsular spread. Studies have shown role of concurrent chemoradiation in an effort to avoid total laryngectomy and preserve organ function.





Highly confirmed dose gradient in a case of carcinoma PFF treated with IMRT by rapid arc technique (True Beam STx, Varian Medical System)

**Gene Therapy:** Gene therapy, and molecular target therapy are being tried in head & neck cancers. Tumor cell-kill is achieved not by genes delivery by the vectors, but by the oncolysis induced by replicated viruses by their original nature.

**Virtual Multidisciplinary Team:** Telemedicine has enabled video- conferencing across distances, and this has helped establish virtual multidisciplinary teams. In countries with fewer resources to establish many multidisciplinary centres, this may be a promising alternative in the future.

**Referrals:** After a case is discussed in TB or MSC, patient's plan of care is planned thereby facilitating referrals and removing treatment barriers. The other interventions include rehabilitation, nutrition and psychological services providing education, increasing awareness on possible changes in speech and swallowing and building of rapport with patients and their families. Early nutrition assessment and timely intervention is a challenge in head and neck cancer patients. Dietician should discuss with patient and family about nutritional requirements when patient is discharged from the hospital.

**Psycho-social Services:** Main role of oncology social worker is to be patient's advocate. The oncology

setting may be confusing and overwhelming to the newly diagnosed patients. The oncology social worker may help patient's and caregivers to navigate through the healthcare systems; they may provide information and expertise in reducing anxiety & depression. The formation of head and neck cancer support groups are powerful tool in assisting patients during and after treatment.

One of the barriers in the implementation of multidisciplinary approach is the financial aspect to sustain cost of medication, nutritional supplements and transportation. Support groups can even assist in funding to bridge the gap in available resources.

### Conclusion

Head and neck cancers require multimodal treatment including surgery, radiation and chemotherapy. Treatment may leave the patient at risk for physical, psychosocial and nutritional issues that directly impact cancer care. A coordinated multidisciplinary approach with good communication facilitates early identification of treatment barriers and improve outcome.

(Dr A K Dewan, Sr Consultant, Surgical Oncology, Medical Director, RGCI&RC)

## GUEST ARTICLE

**THE MULTIDISCIPLINARY CARE OF OROPHARYNGEAL CARCINOMA****Background and Introduction**

Oral and pharyngeal carcinoma represents a significant public health problem worldwide [1], with more than 400,000 new cases per year. India, the United States, and Western Europe have the highest incidences of oropharyngeal cancer (OPC) [1, 2], ranging from 7-17 cases per 100,000 persons. Chaturvedi et al. have recently described the striking new association between oropharyngeal cancer and the human papillomavirus and the startling new epidemiology of OPC [3]. This study estimated population-based incidence of HPV-positive and HPV-negative OPC in the USA using the Surveillance, Epidemiology, and End Results (SEER) database from 1988 to 2004. During this period, HPV-positive OPC increased by 225% (95% CI 208%–242%; from 0.8 per 100,000 to 2.6 per 100,000), whereas the incidence of HPV-negative cancers declined by 50% (95% CI 47%–53%; from 2.0 per 100,000 to 1.0 per 100,000). Patients with HPV-associated OPC tend to be nonsmokers, male, and the young.

In the past, oropharyngeal cancers (OPC) were often treated with disfiguring transfacial, transmandibular approaches [4,5]. yet many patients still required extensive adjuvant therapy post-operatively. Poor function and concern for cosmesis led multidisciplinary teams worldwide to explore alternative options, such as concurrent chemotherapy with radiation therapy [6].

Recently, the Radiation Therapy Oncology Group (RTOG) trial 0129 provided strong evidence that HPV status is an independent prognostic factor for overall survival (OS) and progression-free survival (PFS) among patients with squamous-cell OPC [7]. Furthermore, HPV-positive tumors were exquisitely responsive to concurrent chemotherapy and radiation therapy (ccRT). Locoregional failure at 3 years was 21% lower in patients with HPV-positive tumors 13.6% (95% CI 8.9%–18.3%) versus 35.1% (95% CI 26.4–43.8) for HPV-negative tumors ( $p < 0.001$ ). [7] At 3-yr, overall survival for HPV-positive patients treated with ccRT was 83%, even when T3-4 patients and those with advanced staged lymphadenopathy were included.

Nonetheless, ccRT can be associated with delayed and significant late toxicity, as well as adverse functional side effects, especially in younger patients. In particular, chronic dysphagia remains a major functional impairment in long-term survivors of OPC [8]. Severe (Grade 3-4) late laryngopharyngeal toxicity was reported in 35% of 101 OPC survivors who had adequate baseline function in a pooled analysis of three RTOG trials of concomitant chemoradiotherapy [9], and the 3-year prevalence of dysphagia approaches 50% based on population level data from OPC survivors in the SEER-Medicare database [10].

Despite the advantages of non-surgical “organ-preservation,” concern about long-term toxicity and swallowing function have led some to pursue new approaches [11].

**Transoral Endoscopic Head & Neck Surgery (eHNS)**

Recently, transoral ‘endoscopic’ head and neck surgery (eHNS) [12] has emerged, which comprises of minimally invasive transoral approaches to the oropharynx with laser carbon dioxide (CO<sub>2</sub>) microsurgery (Transoral Laser Microsurgery; TLM) [13] and transoral robotic surgery (TORS) [14]. New surgical approaches provide the hope for improved outcomes without surgical morbidity.

Compared with traditional ‘open’ head and neck surgery, eHNS of the oropharynx is performed without external incisions and obviates the need for mandibulotomy or transmandibular access. This approach can be considered ‘inside-out’ surgery, in that incisions start from the mucosal (inner) surface and extend outward, sparing external skin incisions. Using a laser and microscope for TLM or the da Vinci® Surgical System (Intuitive Surgical Inc., Sunnyvale, CA, USA) for TORS, a complete resection of the index oropharyngeal tumor is performed with an oncological margin. While both TLM and transoral robotic surgery rely on a minimally invasive approach through the mouth, there are some significant differences in these eHNS techniques.

Another therapeutic option for this patient population is TLM, an endoscopic surgical technique performed under direct laryngoscopy, with suspension/fixation and the use of an operating microscope, microsurgical instruments and a CO<sub>2</sub> laser. It is an adaptive surgical technique, relying on the surgeon’s understanding of the 3-dimensional anatomy of the tumor’s extent and



surrounding anatomy. First described in 1972, TLM has a robust literature, although few multicenter experiences have been published and no prospective coordinated clinical trial has been performed [15].

Robotic head and neck surgery was approved for use by the US Food and Drug Administration in 2009. TORS for head and neck cancer (HNC) is performed using three arms, which are placed within the patient's mouth but controlled by a surgeon sitting at a remote console, in a 'master-slave' configuration. A suitable oral retractor is positioned in the mouth and the endoscope or camera is introduced into the pharynx followed by the two other arms carrying interchangeable 5 mm wide working instruments (e.g. grasping forceps and electrocautery). The surgeon is provided with an endoscopically derived 3-dimensional visual display that is co-located with control handles that direct movements of the robot's instruments inside the patient's body. Standard surgical instruments, including tissue forceps, an electrocautery spatula, or CO<sub>2</sub> and thulium laser [16, 17] are then used to perform an en-bloc resection of the oropharyngeal tumour. While the first paper on robotic surgery for OPC was published in 2005, there is little prospective literature examining the role of TORS within the multidisciplinary paradigm.

Both techniques provide a highly magnified view of the tumour, which allows confident resection of various tumour invaginations that are not often visualized with standard surgical techniques. Whereas numerous retrospective single-institution reports and a few important multicentre trials have generated significant enthusiasm for implementing eHNS into the multidisciplinary approach, prospective clinical evidence to support its use is limited. Recently, Adelstein and Ridge hosted an National Cancer Institute (NCI)-sponsored, R13-funded Clinical Trials Planning Meeting to discuss the role of transoral endoscopic surgery for the treatment of OPC [18].

Compared with open surgery, eHNS is minimally invasive. Numerous publications demonstrate a reduction in immediate post-operative toxicity, shorter postoperative hospitalization, and faster functional recovery compared with open surgery [14, 19–21]. Advocates for eHNS (TLM and TORS) in oncological surgery cite excellent functional results and argue that eHNS 'de-intensifies' the long-term toxicity that is sometimes associated with a primary radiation-based approach for OPC [12, 14, 21]. Yet, skeptics of TORS and TLM are wary of this approach, citing concerns

about the relatively 'close' margins and the high rate of post-operative radiation therapy required after eHNS [22].

### Future Perspective/ Conclusion

Despite a surge in interest in eHNS by surgeons, there is no 'level-A' evidence-based clinical data to support its use. Granted, surgery followed by radiation therapy has been the established paradigm for OPC, dating back to the early- and mid-20th century. However, eHNS is a considerable technological advance in surgical technique, akin to the difference between conventional two and three-dimensional conformal radiotherapy (3D-CRT) versus IMRT. Nonetheless, transoral eHNS has been included in the most recent NCCN Guidelines for patients with OPC.

Despite the evolving consensus about the role of minimally invasive approaches to treat OPC, this surgical approach, including the impact of margins and the role of postoperative radiation therapy following TORS and TLM, must be carefully studied, ideally in the setting of a prospective multicenter clinical trial.

Accordingly, in 2014, two NCI-funded prospective clinical trials RTOG 1221 and ECOG 3311 have been launched to study the role of eHNS in patients with OPC.

### References

1. Chaturvedi AK, Anderson WF, Lortet-Tieulent J et al. Worldwide trends in incidence rates for oral cavity and oropharyngeal cancer 2001–2012: a population-based study. *Lancet Oncol* 2013;14(36):4550–59.
2. Chaturvedi AK, Engels EA, Pfeiffer RM, et al. Human papillomavirus and rising oropharyngeal cancer incidence in the United States. *J Clin Oncol* 2011;29:4294–301.
3. Ward GE, Robben JO. A composite operation for radical neck dissection and removal of cancer of the mouth. *Cancer* 1951; 4:98–109.
4. Sugarbaker ED, Gilford J. Combined jaw resection, neck dissection for metastatic carcinoma of cervical lymph nodes secondarily involving the mandible. *Surg Gynecol Obstet*; 1946;83:767–77.
5. Calais G, Alfonsi M, Bardet E et al. Randomized trial of radiation therapy versus concomitant chemotherapy and radiation therapy for advanced-stage oropharynx carcinoma. *J Natl Cancer Inst*. 1999;91(24):2081–86.
6. Ang KK, Harris J, Wheeler R, et al. Human papillomavirus and survival of patients with oropharyngeal cancer. *N Engl J Med*; 2010;363:24–35.
7. Wilson JA, Carding PN, Patterson JM. Dysphagia after nonsurgical head and neck cancer treatment: patients' perspectives. *Otolaryngol Head Neck Surg*. Nov 2011;145(5):767–771.
8. Machtay M, Moughan J, Trotti A, et al. Factors associated with severe late toxicity after concurrent chemoradiation for

locally advanced head and neck cancer: an RTOG analysis. *J Clin Oncol*. Jul 20 2008;26(21):3582-89.

9. Francis DO, Weymuller EA, Jr., Parvathaneni U, Merati AL, Yueh B. Dysphagia, stricture, and pneumonia in head and neck cancer patients: Does treatment modality matter? *Ann Otol Rhinol Laryngol*. Jun 2010;119(6):391-97.
10. Holsinger FC, Weber RS. Swing of the surgical pendulum: A return to surgery for treatment of head and neck cancer in the 21st century? *Int J Radiat Oncol Biol Phys*, 2007;69 (2 Suppl):S129-31.
11. Holsinger FC, Sweeney AD, Jantharapattana K, et al. The emergence of endoscopic head and neck surgery. *Curr Oncol Rep*;2010;12:216-22.
12. Steiner W. Experience in endoscopic laser surgery of malignant tumors of the upper aero-digestive tract. *Adv Otorhinolaryngol*;1988;39:135-44.
13. Weinstein GS, O'Malley BW Jr, Magnuson JS, et al. Transoral robotic surgery: A multicenter study to assess feasibility, safety, and surgical margins. *Laryngoscope* 2012;122:1701-07.
14. Strong MS, Jako GJ. Laser surgery in the larynx: Early clinical experience with continuous CO2 laser. *Ann Otol Rhinol Laryngol* 1972;81:791-98.
15. Desai SC, Sung CK, Jang DW, et al. Transoral robotic surgery using a carbon dioxide flexible laser for tumors of the upper aerodigestive tract. *Laryngoscope* 2008;118:2187-89.
16. Solares CA, Strome M. Transoral robot-assisted CO2 laser supraglottic laryngectomy: Experimental and clinical data. *Laryngoscope*;2007;117:817-20.
17. Adelstein DJ, Ridge JA, Brizel DM, et al. Transoral resection of pharyngeal cancer: Summary of a National Cancer Institute Head and Neck Cancer Steering Committee Clinical Trials Planning Meeting, 6-7 November 2011, Arlington, Virginia. *Head Neck* 2012;34:1681-703.
18. Moore EJ, Olsen SM, Laborde RR, et al. Long-term functional and oncologic results of transoral robotic surgery for oropharyngeal squamous cell carcinoma. *Mayo Clin Proc*; 2012;87:219-25.
19. Hurtuk AM, Marcinow A, Agrawal A, et al. Quality-of-life outcomes in transoral robotic surgery. *Otolaryngol Head Neck Surg* 2012;146:68-73.
20. Functional outcomes after TORS for oropharyngeal cancer: a systematic review. Hutcheson KA, Holsinger FC, Kupferman ME, Lewin JS. *Eur Arch Otorhinolaryngol*. 2014 Mar 19. [Epub ahead of print] PMID: 24643851
21. Garden AS, Kies MS, Weber RS. To TORS or Not to TORS: But is that the question? Comment on "transoral robotic surgery for advanced oropharyngeal carcinoma". *Arch Otolaryngol Head Neck Surg*. 2010;136(11):1085-07.
22. National Comprehensive Cancer Network. Clinical Practice Guidelines in Oncology (NCCN guidelines®) Head and Neck Cancers. Version 1, 2012.

(Dr F Christopher Holsinger, Chief, Head and Neck Surgery, Professor, Dept of Otolaryngology - Head and Neck Surgery Stanford University, CA, USA)

## WATCHOUT

### Mugard Oral Mucoadhesive Hydrogel

Access Pharmaceuticals, Inc. (OTCBB: ACCP), has been granted the Japanese Patent for MuGard and ProctiGard. The patent covers a wide range of liquid formulations for the prevention and treatment of mucosal diseases and disorders. MuGard® Mucoadhesive Oral Wound Rinse is indicated for the management of oral mucositis/stomatitis (that may be caused by radiotherapy and/or chemotherapy) and all types of oral wounds (mouth sores and injuries). MuGard provides the oral mucosa with a thin protective hydrogel layer which has been demonstrated in several clinical studies of mucositis to benefit patients in terms of reduced pain and discomfort as well as a reduction in objective mucositis scores. The trial published in the *Journal, Cancer*, discussed the data on Access post-marketing clinical trial that evaluated the efficacy of MuGard in controlling symptoms caused by oral mucositis in 120 patients receiving chemoradiation therapy for the treatment of cancers of the head and neck.

([www.biospace.com](http://www.biospace.com))

### Methods of Treating Cancer using Inhibitors

Schramm; Vern L. et al of Albert Einstein College of Medicine of Yeshiva University (Bronx, NY) USPTO No. 8,916,6571 Dated 23<sup>rd</sup> December 2014. The invention relates to the treatment of particularly prostate cancer and head and neck cancer using an inhibitor of 5'-methylthioadenosine phosphorylase (MTAP). MTAP is abundantly expressed in normal cells and tissues, and its deficiency due to a genetic deletion has been reported with many malignancies. The loss of MTAP enzyme function in these cells is known to be due to homozygous deletions on chromosome 9 of the closely linked MTAP and p16/MTS1 tumor suppressor gene. As absence of p16/MTS1 is probably responsible for the tumor, the lack of MTAP activity is a consequence of the genetic deletion and is not causative for the cancer. However, the absence of MTAP alters the purine metabolism in these cells so that they are mainly dependent on the de novo pathway for their supply of purines. Compounds that are inhibitors of MTAP have potential for treating cancer, particularly prostate cancer and head and neck cancer.

([www.uspto.org](http://www.uspto.org))



## PERSPECTIVE

## WHY TRANSORAL ROBOTIC SURGERY (TORS)?

In 2012, Ang et al, retrospectively reviewed oncologic outcomes following standard chemoradiation for HPV related OPCA carcinoma treated from a previously completed Radiation Therapy Oncology Group study and found that in HPV related OPCAs fell into three general categories of responders to standard chemoradiation<sup>1</sup>. In this retrospective, but impactful study, Ang et al found 3 year overall survival ranging from 93% to 46.2% depending primarily on whether the cancer was HPV related, smoking history and T and N stage<sup>2</sup>. One of the most important findings in Ang et al was that for patients with greater than 10 pack year smoking history, with a N2b disease, the overall 3 year survival was 67%<sup>2</sup>. Mehanna et al cautioned in an editorial in the British Journal of Medicine that HPV related cancers tend to occur in younger healthier patients frequently with no smoking history and accepting the significant treatment related morbidity in this group was not acceptable<sup>3</sup>. In response to this reality, the focus of study became “deintensification” with numerous prospective “deintensification” research programs focusing on identifying a treatment that would optimize cure in HPV related OPSC while decreasing significant treatment related morbidity of standard chemoradiation<sup>4,5</sup>. In fact a search done today on the term “deintensification” among the 24 million references in the PUBMED yields 28 articles in which 23 of them highlight

the fact that standard chemoradiation regimens are overly morbid for the relatively young and otherwise healthy patients with HPV related OPCA and that deintensification is needed<sup>6</sup>. By the early 2000s it became clear that standard chemoradiation strategies that we were studying at UPENN were associated with significant treatment related morbidity and mortality including late Grade 3 toxicity occurring in 24% of patients in the form of dysphagia, aspiration and soft tissue necrosis as well as a treatment related mortality rate of 4%<sup>7,8</sup>. These untoward treatment outcomes were recognized at the national level as well with a review of RTOG patients treated with oral or oropharyngeal cancer with chemoradiation having a 1% acute treatment related mortality but even more alarming was that for long-term survivors there was a 29% stomach tube dependency rate and a 13% treatment related (non-cancer related) mortality in long-term survivors.<sup>9</sup> There is no question that some of the RTOG trials that Machtay et al studied utilized more aggressive regimens than standard therapy that we utilize for oropharyngeal cancer. However, the results were still telling and the fact that so many non-surgical “de-intensification” trials exist is a testimony to the toxicity of the standard of care regimen presently in use<sup>9</sup>. It was precisely this morbidity and mortality of primary chemoradiation, that we were also seeing at UPENN that prompted us to begin our TORS research program. A recent review written by the former Chief of Head and Neck Radiation Oncology at PENN and now at Hopkins, Quon noted that TORS for oropharyngeal carcinoma was accurately described as not only a low morbidity minimally invasive surgical approach but as a treatment paradigm in which postoperative pathologic

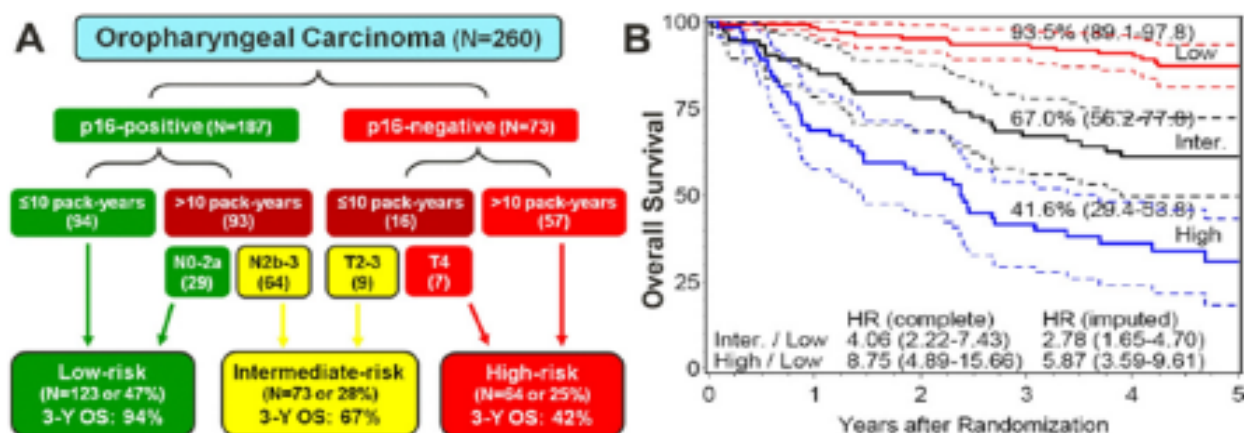


Fig 1: Classification of oropharyngeal cancer patients from RTOG 0129 into three risk-of-death categories by recursive partitioning analysis (A) and Kaplan-Meier estimates of overall survival according to those categories (B). Modified from Ang et al<sup>42</sup> (Color version of figure is available online.)

findings were utilized to triage patients to either no treatment or lower intensity postoperative radiation with or without chemotherapy the goal of which is to improve functional outcomes without compromising oncologic outcomes.<sup>4</sup> Several institutions have reported 0–2.6% gastromy tube dependence following TORS, and excellent quality of life outcomes<sup>10</sup>. A recent retrospective multivariate analysis of 114 HPV related oropharyngeal carcinomas treated with the TORS paradigm at the University of Pennsylvania noted a 3.3% local regional failure and 8.4% distant metastatic rate regardless of the prognostic factors, such as smoking history, T stage or N stage that have been shown to impact on the outcomes with standard chemoradiation<sup>11</sup>. The past year the Eastern Cooperative Oncology Group (ECOG) opened a postoperative adjuvant therapy de-intensification trial, ECOG3311, following TORS as the primary transoral approach with Gregory Weinstein, MD appointed as the Surgical Quality Assurance Co-Chair, with the goal of further deintensifying post-surgical adjuvant therapy for HPV related oropharyngeal cancers.<sup>12</sup>.

## References

1. Ang KK, Sturgis EM. Human papillomavirus as a marker of the natural history and response to therapy of head and neck squamous cell carcinoma. *Seminars in Radiation Oncology* 2012;22:128-42.
2. Ang KK, Harris J, Wheeler R, et al. Human papillomavirus and survival of patients with oropharyngeal cancer. *The New England Journal of Medicine* 2010;363:24-35.
3. Mehanna H, Jones TM, Gregoire V, Ang KK. Oropharyngeal carcinoma related to human papillomavirus. *Bmj*; 2010;340:c1439.
4. Quon H, Richmon JD. Treatment deintensification strategies for HPV-associated head and neck carcinomas. *Otolaryngologic Clinics of North America*, 2012;45:845-61.
5. Marur S, Burtress B. Oropharyngeal squamous cell carcinoma treatment: current standards and future directions. *Current Opinion in Oncology*; 2014;26:252-58.
6. Search on word “deintensification” Pubmed.gov. (Accessed November 30, 2014, 2014, at <http://proxy.library.upenn.edu:2066/pubmed/?term=deintensification>.)wdwdwdf.
7. Machtay M, Rosenthal DI, Hershock D, et al. Organ preservation therapy using induction plus concurrent chemoradiation for advanced resectable oropharyngeal carcinoma: A University of Pennsylvania Phase II Trial. *Journal of Clinical Oncology: official journal of the American Society of Clinical Oncology* 2002;20:3964-71.
8. Mirza N, Machtay M, Devine PA, Troxel A, Abboud SK, Doty RL. Gustatory impairment in patients undergoing head and neck irradiation. *The Laryngoscope*, 2008;118:24-31.
9. Machtay M, Moughan J, Trotti A, et al. Factors associated with severe late toxicity after concurrent chemoradiation for locally advanced head and neck cancer: An RTOG Analysis. *Journal of Clinical Oncology*; 2008;26:3582-9.
10. Adelstein DJ, Ridge JA, Brizel DM, et al. Transoral resection of pharyngeal cancer: Summary of a National Cancer Institute Head and Neck Cancer Steering Committee Clinical Trials Planning Meeting, November 6-7, 2011, Arlington, Virginia. *Head & Neck* 2012;34:1681-703.
11. Kaczmar JM, Tan KS, Heitjan DF, et al. HPV-related oropharyngeal cancer: risk factors for treatment failure in patients managed with primary surgery (TORS). *Head & neck* 2014.
12. E3311 – Phase II Randomized trial of transoral surgical resection followed by low-dose or standard-dose IMRT in resectable p16+ locally advanced oropharynx cancer. (Accessed November, 2014, 2014, at <http://ecog-acrin.org/clinical-trials/e3311-educational-materials>.)

(Dr Gregory Weinstein Professor and Vice-Chair, Director, Division of Head and Neck Surgery, The University of Pennsylvania, Philadelphia, PA 19104, USA)

## The Next Generation Microfluidic System Capturing, Analyzing, & Monitoring CTCs

Circulating Tumor Cells (CTC) enumeration has evolved as an important prognostic marker in different cancers. CTCs escape from the primary tumor, enter the blood or lymph stream and seed secondary tumors in other organs of the body. CTCs are of tremendous scientific interest as they contain key information about the tumor and can therefore be used for early diagnosis and/or treatment. Detecting CTCs is technologically challenging; few cells in a background of billion other normal blood cells.

RGCI & RC has installed Next-Gen Microfluidic Platform which is the *only* system that meets and exceeds the current expectations of cancer diagnostics: It is an integrated and automated system for label-free capture of CTCs as well as downstream single cell immunochemistry, DNA FISH, mRNA, PCR and Cellular analysis and expansion.

- Completely walk away system.
- No manual interventions are required.
- Cells can be harvested into 3 channels for studying immunophenotypes, molecular studies & FISH.
- The system is free of EPCAM based concentration which has received adverse commentary because of reduced EPCAM expression during epithelial mesenchymal transformation.

(For more information contact Dr M Suryavanshi, Consultant, Dept of Pathology Services, Phone: 011-47022408)



## RESEARCH & DEVELOPMENT

### miRNAs Expression and Local Recurrence

Scientists from the Italian National Cancer Institute have shown that expression of 4 prognostic microRNA signature can predict the local recurrence risk in patients with oral squamous cell carcinoma (OSCC). MicroRNAs (miRNAs) are gene regulators playing an important role in oral carcinogenesis. The study aimed to identify and functionally characterize miRNAs that predict recurrence in OSCC. The researchers had collected 92 OSCC with their normal tissue counterparts and performed miRNAs expression profiling on 74 OSCC and 38 normal tissues. The association between the expression of miRNAs and clinical outcome was evaluated in 69 followed-up patients. Four of the miRNAs deregulated between OSCC and normal tissues were prognostic for recurrence either when considered individually or as a group. Depletion of the expression of prognostic miRNAs inhibits the proliferation of OSCC cells. It was concluded that MicroRNAs are differentially expressed in OSCC versus normal samples. The expression of 4 prognostic miRNAs signature is able to predict recurrence risk independently from other clinical factors in OSCC.

*(Head Neck, Dec 22, 2014)*

### MAGEA3/6 as a Marker for Recurrence HNSCC

Cancer testis antigens (CTA) are strong immunogenic proteins with a tumor-restricted expression pattern, and are being considered ideal targets for tumor-specific immunotherapeutic approaches. In a study conducted at Federal University, Brazil, using an in-silico approach, the researchers selected, among 139 previously described CTA, candidates to be evaluated in 89 HNSCC and 20 normal mucosa samples. SPANX-CD (71.9%), MAGEB2 (44.9%), MAGEA1 (44.9%), MAGEB6 (32.6%) and CXORF48 (27.0%) were found frequently expressed in HNSCC, and over 85% of the tumors expressed at least one of these five CTA. The mRNA positivity of CXORF48, MAGEB6, and CRISP2 presented significant associations with recognized clinical features for poor outcome. Furthermore, MAGEA3/6 positivity was associated with significantly better disease-free survival (DFS,  $p=0.014$ ) and the expression of this antigen showed to be an independent prognostic factor for tumor recurrence. It was concluded that one of the five selected CTA could be possible targets for

immunotherapeutic approaches, and the mRNA-positivity for MAGEA3/6 showed to be an independent marker for disease-free survival.

*(Mol Cancer Ther, Jan 6, 2015)*

### Novel Prognostic Model Oral Tongue Cancer

The prognostication of patient outcome is one of the greatest challenges in the management of early stage oral tongue squamous cell carcinoma (OTSCC). In a multicentric study, a simple histopathological model for the prognostication of survival in patients with early OTSCC was used. 311 cases from different centres with clinically evaluated early stage OTSCC (cT1-T2cN0cM0) were included. Tumor budding (B) and depth of invasion (D) were scored on haematoxylin-eosin-stained cancer slides. The cut-off point for tumor budding was set at 5 buds (low  $<5$ ; high  $\geq 5$ ) and for depth of invasion at 4mm (low  $<4$ mm; high  $\geq 4$ mm). The scores of B and D were combined into one model: the BD predictive model. On multivariate analysis, a high risk score (BD score 2) correlated significantly with loco-regional recurrence ( $P=0.033$ ) and death due to OTSCC ( $P<0.001$ ) in early stage OTSCC. The new BD model is a promising prognostic tool to identify those patients with aggressive cases of early stage OTSCC who might benefit from multimodality treatment.

*(Int J Oral Maxillofac Surg Nov 11, 2014)*

### Nucleic Acid Amplification Assay in Head and Neck Cancer

The investigators from Fukushima Medical University School of Medicine, Japan have shown one-step nucleic acid amplification (OSNA) based on CK19 expression in the primary lesions of head and neck squamous cell carcinoma. The study investigated the effects of CK19 expression in the primary lesions of HNSCC on the diagnosis of the cervical lymph node (CLN) metastasis using the OSNA assay. A primary lesions and 54 cervical lymph node CLNs were resected from 21 patients with HNSCC between 2009 and 2011. Each CLN was tested by the OSNA assay, and the CK19 mRNA copy number obtained was compared with the corresponding histopathological results. In the primary lesion CK19-positive group, the sensitivity and specificity of the OSNA assay against hematoxylin-eosin staining were 86% and 100%, respectively. These findings were statistically significant. The results suggest that OSNA offers similar diagnostic potential to that of histopathological diagnosis of CLN biopsy in patients with a CK19-positive primary lesion.

*(Head Neck, Dec 24, 2014)*

## NEW TECHNOLOGIES

### Blood and Saliva Tests to Predict Recurrence

Human papillomavirus type 16 (HPV-16) is a major causative factor in oropharyngeal squamous cell carcinoma (OPSCC). The incidence of HPV-related oropharyngeal cancers has been increasing of late, outpacing oropharyngeal cancers due to tobacco and alcohol use. Scientists at John Hopkins, Baltimore have developed blood and saliva tests that help accurately predict recurrences of HPV-linked oral cancers. The tests screen for DNA fragments of the HPV-16 shed from cancer cells and remaining in the mouth or other parts of body. The patients with HPV-related oropharyngeal cancers are usually examined every one to three months in the first year after the diagnosis. Recurrences are often found when patients report ulcers, pain or lumps in the neck. The imaging tests are unpredictable in finding recurrence earlier and the location of oropharyngeal cancers in the tonsils, throat and base of tongue makes it hard to spot the budding lesions. The research team analyzed blood and saliva samples from 93 treated oropharyngeal cancer patients. The samples were collected before and after the treatment. A total of 81 patients had HPV-16-positive tumors. Real-time quantitative polymerase chain reaction was used to detect HPV-16 E6 and E7 DNA in saliva and plasma samples. The scientists found that HPV-16 DNA detected in patients' saliva after treatment was predictive for recurrence for about 20% of the time in a subset of patients. The precision increased to more than 55% when the HPV-16 DNA was looked for in the plasma of another subset. This further predicted recurrence 70% of the time in a third subset wherein both plasma and saliva samples were tested. The researchers concluded that using a combination of pretreatment plasma and saliva can increase the sensitivity of pretreatment HPV-16 status as a tool for screening patients with HPV-16-positive OPSCC. In addition, the analysis of HPV-16 DNA in saliva and plasma after primary treatment may allow for early detection of recurrence in patients with HPV-16-positive OPSCC.

*(JAMA Otolaryngol Head Neck Surg, Sep, 2014)*

### Lymphoseek to Determine Extent of Disease

The US Food and Drug Administration has approved a new use for lymphoseek (technetium 99m tilmanocept) injection to help determine the extent of metastatic head and neck cancer in body. In 2013, Lymphoseek, a radioactive diagnostic agent, was approved to help identify lymph nodes to a primary tumor in patients with breast cancer or melanoma. The safety and efficacy of Lymphoseek were established in a clinical trial of 85 patients with squamous cell carcinoma of lip, oral cavity and skin. Further, the suspected lymph nodes, those identified by Lymphoseek and those based upon tumor location and surgical practice were removed for pathological examination. The results showed that Lymphoseek guided sentinel lymph node biopsy accurately determined if cancer had spread through the lymphatic system. The most common side effects identified in clinical trial were pain or irritation at the injection site. This new indication would allow for the option of more limited lymph node surgery in patients with sentinel nodes negative for cancer.

*(US FDA, Jun 13, 2014)*

### Robotic Surgery for Inoperable Tumors

Researchers at University of California, Los Angeles have advanced a surgical technique performed with the aid of a robot to successfully access a previously unreachable area of the head and neck. The pioneering method makes the use of a minimally invasive procedure as Trans Oral Robotic Surgery (TORS) during which a surgical robot, under the full control of a specially trained physician, operates with a three-dimensional high-definition video camera. TORS can now be used to operate within the parapharyngeal space, a pyramid shaped area near the base of human skull. It is lined with many large blood vessels, nerves and complex facial muscles making access to the space with traditional methods often impossible. Controlled by the surgeon, the robotic arms navigate through the tight and delicate areas of the mouth without necessitating any external incisions. The patients may lead normal, healthy lives in a few days with less or even no side effects. The new approach provides the surgical community with a leading-edge technology roadmap to treat patients who had little or no hope of living cancer-free lives.

*(Medical News Today, Dec 10, 2014)*



## CLINICAL TRIALS

### Afatinib for Metastatic Head and Neck Cancer

According to the results of phase III trial tyrosine kinase inhibitor afatinib significantly improved progression-free survival compared to methotrexate in patients with recurrent or metastatic squamous cell carcinoma of the head and neck after failure of platinum-based chemotherapy. The improvement in progression-free survival was associated with a significant delayed worsening of symptoms such as pain, swallowing and global health. Researchers recruited 483 patients with recurrent or metastatic head and neck squamous cell carcinoma whose cancer had progressed despite treatment with platinum-based therapy. Of these patients, 322 patients received 40 mg/day oral afatinib and 161 were given 40 mg/m<sup>2</sup>/week intravenous methotrexate. As per the primary endpoint, afatinib improved progression-free survival and delayed worsening of symptoms. The most frequent grade 3/4 drug-related adverse events were rash/acne (9.7%) and diarrhea (9.4%) which were also manageable with afatinib.

*(Science daily, Sep 2014)*

### Benzydamine Oral Rinse for Mucositis

Radiation-induced mucositis is a common toxicity for head and neck cancer and is associated with both short and long-term functional consequences. To reduce the burden of mucositis, a double-blind placebo-controlled randomized clinical trial is done with the aim to evaluate the efficacy of benzydamine oral rinse in prevention and management of radiation-induced oral mucositis. Fifty-one patients with head and neck carcinoma were randomized for treatment with either benzydamine oral rinse or placebo, initiated the day before radiotherapy and continued for 2 weeks after the end of treatment. A score was given to each site based on the degree of mucositis and "mean mucositis score" was calculated. As per the results mean score of placebo group was more than that of treatment group (1.81 vs 1.27,  $P = 0.001$ ) at the end of 4 weeks and the trend continued till end of 7 weeks. Through this study, it was confirmed that benzydamine oral rinse is safe, effective and well-tolerated.

*(Asia Pac J Clin Oncol, Dec 2014)*

### Voice Quality after Treatment of Early Vocal Cord Cancer

Researchers at Helsinki University Central Hospital, Finland performed a randomized trial comparing laser surgery with radiation therapy to assess the quality of voice achieved with these treatments. Total 60 male patients with early laryngeal cancer were randomly assigned in the trial. Of these 32 patients received laser surgery with CO<sub>2</sub> laser and 28 patients received external beam radiation therapy. External beam radiation therapy with cumulative dose of 66 Gy was delivered to the larynx in 2-Gy daily fractions over 6.5 weeks. The outcome measures were expert-rated voice quality on a grade, roughness, breathiness, asthenia, strain scale, videolaryngostroboscopic findings, and the patients' self-rated voice quality. Voice quality was reviewed at baseline and 6 and 24 months after treatment. Results showed that patients treated with radiation therapy had less hoarseness and less breathy voice in comparison to laser surgery treated patients. It was concluded that, radiation therapy should be treatment for patients who need better voice quality. However, while choosing the treatment options, patient-related factors should also be considered.

*(Int J Radiat Oncol Biol Phys, Oct 2014)*

### Immunonutrition for Head & Neck Cancer

A double-blind randomized clinical trial was performed to assess effect of immunonutrition in perioperative patients of head & neck cancer patients treated by radiochemotherapy (RCT) to reduce complications and length of hospital stay. The trial recruited 28 patients, randomized into two groups, receiving either an immunomodulating enteral nutrition formula (IEN,  $n = 13$ ), or an isoenergetic isonitrogenous standard enteral nutrition formula (SEN,  $n = 15$ ) throughout RCT (5-7 weeks). Immune cells metabolism and functions were assessed at the beginning (Db) and at the end (De) of RCT. Immunonutrition maintained CD4<sup>+</sup>/CD8<sup>+</sup> T-lymphocyte counts ratio and CD3 membrane expression between Db and De. Polymorphonuclear cells CD62L and CD15 densities and ROS production were increased in IEN patients. Through these results it could be concluded that immunonutrition can enhance immune cell responses and also help the patients to adapt to the systemic inflammation and oxidative stress induced by RCT.

*(Clin Nutr, Dec 2014)*

## CANCER CONTROL

### Body Size and Risk of Head and Neck Cancers

In a multicentric study researchers from Iran, United Kingdom, and United States analyzed the association between body size and head and neck cancers (HNCA). In this prospective NIH-AARP cohort study, 218,854 participants (132,288 men and 86,566 women), aged 50 to 71 years, were cancer free at baseline (1995 and 1996), and had valid anthropometric data. Until December 31, 2006, 779 incident HNCAs occurred: 342 in the oral cavity, 120 in the oro- and hypopharynx, 265 in the larynx, 12 in the nasopharynx, and 40 at overlapping sites. There was an inverse association between HNCA and body mass index, which was almost exclusively among current smokers (HR = 0.76 per each 5 U increase; 95% CI, 0.63-0.93), and diminished as initial years of follow-up were excluded. A direct association was observed with waist-to-hip ratio (HR = 1.16 per 0.1 U increase; 95% CI, 1.03-1.31), particularly for cancers of the oral cavity (HR, 1.40; 95% CI, 1.17-1.67). Height was also directly associated with total HNCAs ( $P = 0.02$ ), and oro- and hypopharyngeal cancers ( $P < 0.01$ ). It was concluded that the risk of HNCAs was associated inversely with leanness among current smokers, and directly with abdominal obesity and height.

*(Cancer Epidemiol Biomarkers Prev, Nov 2014)*

### Mediterranean Diet and the Risk of Oral and Pharyngeal Cancer

A multicentric study by Italy and Switzerland have shown beneficial role of the Mediterranean diet on oral cavity and pharyngeal (OCP) cancer. The researchers have analysed data from a case-control study carried out between 1997 and 2009 in Italy and Switzerland, including 768 incident, histologically confirmed OCP cancer cases and 2078 hospital controls. Adherence to the Mediterranean diet was measured using the Mediterranean Diet Score (MDS) based on the major characteristics of the Mediterranean diet, and two other scores, the Mediterranean Dietary Pattern Adherence Index (MDP) and the Mediterranean Adequacy Index (MAI). Researchers have estimated the odds ratios (ORs), and the corresponding 95%

confidence intervals (CI), for increasing levels of the scores (i.e., increasing adherence) using multiple logistic regression models. They found a reduced risk of OCP cancer for increasing levels of the MDS, the ORs for subjects with six or more MDS components compared with two or less being 0.20 (95% CI 0.14-0.28,  $P$ -value for trend  $<0.0001$ ). The ORs for the highest vs the lowest quintile were 0.20 (95% CI 0.14-0.28) for the MDP score (score 66.2 or more vs less than 57.9), and 0.48 (95% CI 0.33-0.69) for the MAI score (score value 2.1 or more vs value less than 0.92), with significant trends of decreasing risk for both scores. The favourable effect of the Mediterranean diet was apparently stronger in younger subjects, in those with a higher level of education, and in ex-smokers, although it was observed in other strata as well. The study provides strong evidence of a beneficial role of the Mediterranean diet on OCP cancer.

*(Br J Cancer, Aug 26, 2014)*

### Serum Fatty Acids in Beef Consumption and Salivary Gland Tumors

Researchers from the Universidad Nacional de Córdoba, Argentina have found a negative association of serum oleic and linoleic with the salivary gland tumors (SGT). The objective of the present study was to analyze beef consumption, conjugated linoleic acid (CLA) and n-3 fatty acid (FA) serum concentration and their relation to salivary gland tumors (SGT). In this study researchers used a questionnaire on non-nutritional risk factors and a validated food frequency questionnaire in 20 SGT and 20 control patients. Serum CLA was analyzed by chromatography and the data were analyzed statistically. Non-significant differences were found between SGT and control regarding lean and fatty beef consumption and serum CLA. Serum n-3 linolenic acid concentration was higher in control than in SGT ( $p=0.004$ ). No associations between beef consumption and CLA serum concentration were found, but a strong-positive association between total energy intake and total fat intake and SGT were observed. A significant inverse association between oleic and linoleic FA intake and SGT was recorded. The study concluded that serum oleic and linoleic FAs showed a significant negative association with SGT.

*(Anticancer Res, October 2014)*



## GLOBE SCAN

### Difference in Location of Oral Cancers

Relatively high incidence of mouth squamous cell cancer in nonsmokers, especially women, without obvious causes has been noted. Traditionally, head and neck squamous cell cancer (HNSCC) has been associated with the five “S’s” of smoking, spirits, syphilis, spices and sharp (or septic) teeth. The author sought to examine whether oral cavity cancers occurred more commonly at sites of dental trauma and how that varied between nonsmokers without major identified carcinogens and smokers. Their study was based on analysis of 724 patients with oral cavity or oropharyngeal cancers seen at an Australian hospital between 2001 and 2011. Of the 334 patients with oropharyngeal cancer, 48 were lifelong nonsmokers, 266 current smokers and 20 former smokers. Of the 390 patients with mouth cancer, 87 were lifelong nonsmokers, 276 current smokers and 27 former smokers. Study results show that oral cancers occurred on the lateral (edge of) tongue in 57 nonsmokers (66 percent) compared with 107 smokers/former smokers (33 percent). This data supports the limited evidence from the small number of previous studies that recognized a potential role of chronic dental irritation in carcinogenesis”.

*(Australia: JAMA Otolaryngology-Head & Neck Surgery, Nov 6, 2014)*

### Diagnostic Value of CNB and FNAC

Core-needle biopsy (CNB) has gained acceptance as a minimally invasive procedure in the head and neck. Nevertheless, many concerns arise regarding the value and safety of this method in the assessment of salivary gland lesions. A prospective study comprising 111 patients with a salivary gland lesion was done. The results of ultrasound-guided CNB were compared with those of fine-needle aspiration (FNA) in the 103 histologically verified cases. CNB achieved a higher accuracy than FNA in identifying true neoplasms (98% vs 91%) and detecting malignancy (99% vs 87%), and was also superior to FNA in providing a specific diagnosis (93% vs 74%). CNB is a simple, safe and highly accurate procedure, which should be considered as an additional diagnostic tool in the assessment of salivary gland lesions.

*(Switzerland: Head Neck, Jan 10, 2015)*

### Pain Intensity to Predict Survival

Researchers at MD Anderson Cancer Center assessed the extent to which pain severity influences survival in 2340 newly diagnosed patients with head and neck cancer. At first presentation, patients rated their pain using a scale in which 0 meant no pain and 10 indicated “pain as bad as you can imagine. Pain often is the first sign of head and neck cancer, as a result of destructive lesions and direct tissue and bone involvement. Results of the study showed that severe pain was reported by 19 percent of the sample, and was most prevalent in patients with oral cancer (20 percent). Pain intensity varied based on tumor stage, fatigue, smoking status and comorbid lung disease. Eight hundred twenty eight patients died. Among those with oral cancer, overall five-year survival was 31 percent for patients who reported severe pain and 52 percent for those without severe pain. The authors concluded that pretreatment pain severity in head and neck cancer patients is an independent predictor of overall five-year survival. They noted that patients who present with severe pain at diagnosis should be closely monitored and promptly treated for pain symptoms.

*(USA: Journal of Pain, Oct 27, 2014)*

### F-18 FDG PET/CT in Head and Neck Cancers

It has been previously reported that metabolic tumor volume (MTV) on positron emission tomography-computed tomography predicts disease recurrence and death in head and neck cancer. In this study, the authors assessed the prognostic value of MTV measured using F18-Fluorodeoxyglucose PET/CT in patients with head and neck squamous cell carcinoma. They analyzed the imaging findings of 74 patients (age  $57 \pm 16$ ) retrospectively, with head and neck cancer who underwent PET/CT scan for staging and after treatment. The MTVs of primary sites with or without lymph nodes were measured and outcomes were assessed using the treatment response evaluation. A total of 48 patients had complete response or no recurrence was detected as in the last follow-up. Of the first PET/CT scan, the median primary tumor SUV<sub>max</sub> was 18.8 and the median nodal SUV<sub>max</sub> was 13.4. The median primary tumor MTV% 50s ranged from 11.12 cm<sup>3</sup> to 16.28 cm<sup>3</sup>, and the MTV after the therapy ranged from 1.18 cm<sup>3</sup> to 3.51 cm<sup>3</sup>. MTV represents tumor burden, which shows F18-FDG uptake and has a potential value in predicting short-term outcome and disease-free survival in patients with head and neck cancer.

*(Turkey: J Cancer Res Ther, Oct-Dec, 2014)*

## IN FOCUS

### NEXT GENERATION SEQUENCING (NGS) TESTS AND HEAD AND NECK CANCER

The mode of deciding the best course of treatment for a patient has come a long way. Hippocrates, the father of Western medicine, postulated the use of combined examination of the four humors: blood, phlegm, black bile and yellow bile, to assess a patient's condition and treatment. Interestingly, the concept of personalized medicine, an approach finding widespread application in today's medicine, relies on sequencing of the four chemical building blocks making up a patient's DNA.

Personalized medicine has tremendous scope in cancer, given the genetic diversity present in the tumor cells of a single patient. Malignant transformation of cells is essentially caused by a unique set of somatic mutations. Somatic mutations are mutations that are not present at birth, ie, in the germ cells, but are acquired later in life. These mutations can occur anywhere in the body and cannot be passed on to the next generation. Accumulation of somatic mutations within the cell can lead to unrestrained cellular proliferation and establishment of cancer.

Head and neck cancer accounts for ~4% of all malignancies worldwide, though it constitutes 40% of the cancer burden in India. The distinct geographic predilection of head and neck squamous cell carcinoma (HNSCC), a major portion of the burden being laryngopharyngeal cancers, may be due to prevalence of risk factors and genetic susceptibility. Advances in treatment strategies have not been accompanied by a parallel improvement in the survival rates, the major reasons being late presentation, high recurrence rate and the development of multiple primary tumors (10-30%) [1,2,3]. Detection and identification of patients who are likely to respond to treatment so as to avoid unnecessary toxicity through identifying response/resistant markers are the critical questions that need to be addressed through a comprehensive and systematic approach. The translation of this knowledge database into clinical benefit is also the requirement of the moment.

Expression profiling has led to a few clinically applied molecular classifiers in head and neck cancer such as cisplatin resistance in HNSCC [4], radio-resistance in nasopharynx [5] and a 17-gene signature that correlated with locoregional failure in laryngopharyngeal cancers

[6]. Expression based approach has various limitations such as oversight of clinical behavior of the tumor depending on the mutation pattern, which are overcome to a large extent by deep sequencing of tumors.

### Molecular Profiling of Mutational Landscape of the Tumor

The inherent molecular complexity and heterogeneity of cancer adds enormous value to profiling the underlying mutations in a tumor. Identification of genes that drive tumorigenic pathways can provide a comprehensive understanding of the processes at work in an individual's cancer and potentially provide personalized therapy options. At its onset, personalized medicine in cancer consisted of genetic testing for mutations in a single gene, typically known as the 'driver' mutation in a gene. This was followed by treatment with targeted therapies using drugs that targeted pathways specific and essential to the growth and spread of that cancer. These therapies provided a more effective and less toxic treatment options than conventional chemotherapy and radiotherapy. However, it is becoming increasingly apparent that in many cases, detection of mutations in a single gene alone may not be sufficient. The redundancy and multi-layer control of pathways in cancer cells underlay the lack of response in certain individuals positive for 'driver' mutations, making it necessary for a deeper look at the genetic makeup of the tumors.

### Next Generation Sequencing in Personalized Medicine

With the advent of improved sequencing technologies such as Next Generation Sequencing (NGS), profiling a tumor to detect therapeutically relevant mutations is becoming an increasingly viable option. NGS based tests can typically profile a few hundred genes causally implicated and clinically relevant in cancer. This deep sequencing technology can detect mutations with far greater sensitivity than other conventional sequencing methods, thus making it ideal to study tumors. The application in head and neck cancer has been very nascent; NGS technique accompanied with extensive bioinformatics platforms have identified pathognomonic fusion transcripts in a few uncommon head and neck cancers such as muco-epidermoid carcinoma (MEC), adenoid cystic carcinoma (ACC), and NUT midline carcinoma (NMC) [7].

The systematic cataloguing of cancer mutations by large institutes, such as the Sanger Institute (COSMIC,



<http://cancer.sanger.ac.uk/cancergenome/projects/cosmic>), and consortia, such as ICGC (<http://icgc.org>) have facilitated the identification of such genes. Improved bioinformatics tools to perform careful analysis of the enormous genomic data generated, aid in identification of mutations. According to the COSMIC database, the most frequently mutated genes in head and neck cancer include *TP53*, *CDKN2A*, *PIK3CA*, *MET*, *HRAS*, *EGFR*, *PTEN*, *BRAF*, *KRAS*, *PIK3R1*, *IL6ST*, *JAK3*, *NFE2L2*, and *FBXW7*. In depth assessment of the impact of these mutations can yield therapeutically relevant insights. Frequently, mutations are detected in multiple genes. Results obtained could indicate poor response to a particular regimen that would be typically considered for the patient. Some mutations may be indicators of overall prognosis or response to certain types of chemotherapy. Some of these 'actionable' mutations indicate response to a different drug regimen, and uncovering new therapeutic options. Moreover, it is increasingly being appreciated that tumors of different origins can have the same driver mutations and hence can be targeted using the same drug. For example, cetuximab has been approved by FDA for colorectal cancer and more recently, for head and neck cancer as well. This also supports the idea of testing a tumor for mutations and genes other than the ones associated with that tumor at present. Thus profiling a tumor can help build a potentially actionable landscape of mutations facilitating minimal loss of time before arriving at the most effective therapy plan. This has also spawned a new approach to treatment of cancer where based on the underlying mutations, drugs approved for certain cancers are also being considered and are in trials for other cancer types.

### Utility of NGS in Head and Neck Cancer

More than 90% of the head and neck cancer patients over-express EGFR, either due to amplification of the EGFR gene or polymorphic mutations [8, 9], and thus, anti-EGFR drugs provide a therapeutic window. FDA has approved cetuximab, the anti-EGFR monoclonal antibody, for treatment of advanced head and neck cancers. Approval of cetuximab was based on clinical trials which reported improved survival of head and neck cancer patients with the use of cetuximab in combination with either platinum-based chemotherapy in the recurrent or metastatic setting, or radiotherapy for patients who are not able to derive benefit from platinum-based agents [10, 11]. Although the results from the clinical trials are promising, there are a few caveats to be considered. Firstly, over-expression of EGFR results in higher levels of activated EGFR leading to increased activation of the

downstream RAS/RAF/MEK/ERK1/2 signaling pathway stimulating cell proliferation [12]. Such tumors are an ideal candidate for treatment with cetuximab but the presence of an activating mutation in the downstream pathway such as codon 12 or 13 mutation in *KRAS* would make the tumor refractory to anti-EGFR drugs. Head and neck cancer patients harbouring mutations in the RAS/RAF/MEK pathway will probably fail to respond to cetuximab and treatment with inhibitors of downstream proteins such as MEK inhibitors, trametinib or selumetinib, might be beneficial [13, 14]. Secondly, various clinical studies have reported that after the early response to cetuximab, head and neck tumors gradually acquire resistance to treatment [15, 16]. In such cases, mutation profile of the tumor can help in charting out a second line of treatment or a more aggressive first line treatment. Head and neck cancer patients often harbor activating mutations in *PIK3C*, *PTEN*, or *AKT1* resulting in constitutive activation of the PI3K/mTOR/AKT pathway and thus, possibly sensitizing the tumors to mTOR inhibitors such as everolimus or temsirolimus. Various clinical trials are currently underway to assess the efficacy of mTOR inhibitors or AKT inhibitors as monotherapy or in combination with either cetuximab or chemotherapy in head and neck cancer patients [17].

### Strand Somatic 48 Gene Test

Strand Somatic 48 gene test is a NGS based genomic test that analyzes and interprets significant mutations accrued in the tumor sample compared to normal specimen. The Strand Somatic 48 gene test examines critical regions of 48 genes that are most commonly seen to be mutated in various cancer types. The DNA extracted from the tumor sample (FFPE block) of the patient is sequenced and then analyzed using the NGS analysis platform from Strand Life Sciences that runs modules for aligning sequences and identifying mutations. The genetic information obtained after NGS is unique for each patient and is interpreted using the in-house clinical genomics interpretation and reporting platform, StrandOmics, that has its strength in an extensively curated cancer literature database. Lastly, the Strand Somatic 48 gene test delivers a report describing the clinical utility, i.e therapeutic and prognostic, of the mutations observed in the patient tumor sample.

### Head and Neck Cancer Case Studies at Strand

Till date, a few head and neck cancer samples have been analyzed and interpreted by the Strand Somatic 48 gene test. The following information highlights the mutation profile and clinical utility of the cases undertaken:

- **ATM and TP53:** Patient mutation profiles included genes such as *ATM* and *TP53*. Mutations in *ATM* and *TP53* predict resistance to radiotherapy and to chemotherapy such as cisplatin, respectively [18, 19].
- **PTEN:** One mutation profile included a loss of function mutation in *PTEN* indicating an activated PI3K/AKT/mTOR pathway and such tumors might be sensitive to PI3K/AKT/mTOR inhibitors [20]. Clinical study in patients with head and neck squamous cell carcinoma with activated PI3K or *PTEN* loss, demonstrated response to temsirolimus, an mTOR inhibitor approved for renal cell carcinoma, either as a single agent or in combination with bevacizumab [21]. Evidence from clinical studies in head and neck cancer patients carrying *PIK3CA* mutations or *PTEN* loss indicate possible lack of response to cetuximab [22]. Hence, based on the mutation profile inclusion of mTOR inhibitor to the therapy regimen was suggested.
- **KRAS:** Codon 12 mutation in *KRAS* was observed in another case. As discussed previously, it was inferred that the patient might be refractory to anti-EGFR drugs such as cetuximab but may respond to downstream inhibitors of RAF/MEK pathway [14]. Based on evidence from other tumor types, it was suggested that RAF inhibitors such as sorafenib or MEK inhibitors such as trametinib might be beneficial [14, 23].

In summary, molecular profiling of head and neck tumors promises therapeutic advantage to the patients. Identification of clinically significant mutations can result in deeper insights that can guide therapeutic decisions. Treatment regimens that are aided by such an approach are likely to translate into tailored, less toxic and more cost-effective care.

## References

1. Partridge M *et al.*, Detection of minimal residual cancer to investigate why oral tumors recur despite seemingly adequate treatment. *Clinical Cancer Research* 2000. 6(7): p. 2718.
2. Shah J *et al.*, Cervical lymph node metastases—diagnostic, therapeutic, and prognostic implications. *Oncology (Williston Park, NY)*, 1990. 4(10): p. 61-69.
3. Day GL, B.W. *et al.*, Second primary tumors in patients with oral cancer. *Cancer* 1992. 70(1): p. 14-19.
4. Higuchi E *et al.*, Differentially expressed genes associated with CIS-diamminedichloroplatinum (II) resistance in head and neck cancer using differential display and CDNA microarray. *Head Neck*, 2003. 25(3): p. 187-93.
5. Chang, JT, *et al.*, Differentially expressed genes in radioresistant nasopharyngeal cancer cells: gp96 and GDF15. *Mol Cancer Ther*, 2007. 6(8): p. 2271-79.
6. Ganly I *et al.*, Identification of angiogenesis/metastases genes predicting chemoradiotherapy response in patients with laryngopharyngeal carcinoma. *J Clin Oncol*, 2007. 25(11): 1369-76.
7. Bhaijee F *et al.*, New developments in the molecular pathogenesis of head and neck tumors: A review of tumor-specific fusion oncogenes in mucoepidermoid carcinoma, adenoid cystic carcinoma, and NUT midline carcinoma. *Ann Diagn Pathol*, 15(1): 69-77.
8. Li H *et al.*, Molecular profiling of HNSCC cells and tumors reveals a rational approach to preclinical model selection. *Mol Cancer Res* 2014. 12(4):571-82.
9. Wheeler S *et al.*, Tumor epidermal growth factor receptor and EGFR PY1068 are independent prognostic indicators for head and neck squamous cell carcinoma. *Clin Cancer Res* 2012. 18(8):2278-89.
10. Vermorken JB *et al.*, Platinum-based chemotherapy plus cetuximab in head and neck cancer. *New Engl J Med* 2008. 359(11):1116-27.
11. Bonner JA *et al.*, Radiotherapy plus cetuximab for locoregionally advanced head and neck cancer: 5-year survival data from a phase 3 randomised trial, and relation between cetuximab-induced rash and survival. *Lancet Oncol* 2010. 11(1):21-28.
12. Roberts PJ and Der CJ. Targeting the Raf-MEK-ERK mitogen-activated protein kinase cascade for the treatment of cancer. *Oncogene* 2007. 26(22):3291-3310.
13. Peeters *et al.*, Randomized phase III study of panitumumab with fluorouracil, leucovorin, and irinotecan (FOLFIRI) compared with FOLFIRI alone as second-line treatment in patients with metastatic colorectal cancer. *J Clin Oncol* 2010; 28(31):4706-13.
14. Walters *et al.*, Inhibition of the growth of patient augmented by combined treatment with the epidermal growth factor receptor/HER2 inhibitor lapatinib. *Neoplasia*, 2013; 143-55.
15. Boeckx C *et al.*, Antiepidermal growth factor receptor therapy in head and neck squamous cell carcinoma: focus on potential molecular mechanisms of drug resistance. *Oncologist* 2013;18(7):850-64.
16. Rebutti M *et al.*, Mechanisms underlying resistance to cetuximab in the HNSCC cell line: Role of AKT inhibition in bypassing this resistance. *Int J Oncol*, 2011;38(1): 189-200.
17. Simpson DR *et al.* Targeting the PI3K/AKT/mTOR pathway in squamous cell carcinoma of the head and neck. *Oral Oncol*, 2014. pii: S1368-8375(14)00351-0.
18. Parikh *et al.* Loss of distal 11q is associated with DNA repair deficiency and reduced sensitivity to ionizing radiation in head and neck squamous cell carcinoma. *Genes Chromosomes Cancer*, 2007; 46:761-75.
19. Perrone *et al.*, TP53 mutations and pathologic complete response to neoadjuvant cisplatin and fluorouracil chemotherapy in resected oral cavity squamous cell carcinoma. *J Clin Oncol*, 2010. 28:761-6.
20. Courtney KD *et al.*, The PI3K pathway as drug target in human cancer, *J Clin Oncol*, 2010. 28(6):1075-83
21. Holsinger FC *et al.* Biomarker-directed therapy of squamous carcinomas of the head and neck: Targeting PI3K/PTEN/mTOR pathway. *J Clin Oncol*, 2013. 31:e137-40.
22. Burtneiss *et al.*, Activity of cetuximab (C) in head and neck squamous cell carcinoma (HNSC) patients (pts) with *PTEN* loss or *PIK3CA* mutation treated on E5397, a phase III trial of cisplatin (CDDP) with placebo (P) or C. *J. Clin Oncol*, 2013. 31suppl; abstr 6028
23. Dingemans *et al.* (2013) A phase II study of sorafenib in patients with platinum-pretreated, advanced (Stage IIIB or IV) non pretreated, advanced (Stage IIIB or IV) non-small cell lung cancer with a *KRAS* mutation. *Clin Cancer Res* 19(3):743-51.

(Dr Urvashi Bahadur, Associate Director, Medical Genetics and Genomics, Strand Center for Genomics & Personalized Medicine, Bangalore)



## ABSTRACTS OF PAPERS PUBLISHED BY RGCI & RC IN 2014

### 1. Retrospective Analysis of Treatment Outcomes Following Reirradiation in Locoregionally Recurrent Head and Neck Cancer Patients: A Single Institutional Study.

*Asia Pac J Clin Oncol. Aug 2014*

*Kakria A, Rawat S, Bhutani R, Gupta G, Devnani B, Wahi IK, Ahlawat P*

**Aim:** To present a retrospective analysis of treatment outcomes following reirradiation in locoregionally recurrent head and neck cancer patients at our institute.

**Methods:** Thirty-one patients of head and neck cancer who presented with a locoregional recurrence from April 2007 to April 2012 underwent salvage reirradiation. Median dose of first-time radiation was 70 Gy. Median duration of gap between the first and second course of radiation was 45.6 months. The median dose of reirradiation was 60 Gy. Conformal radiotherapy technique in the form of intensity modulated radiotherapy was used in 60% (17) of patients. Fourteen patients received concurrent chemotherapy or immunotherapy. **Results:** After a median follow-up of 20.6 months, 12 patients were alive with no evidence of disease. The 3-year disease-free survival and overall survival were 28.7 and 48.5%, respectively. Acute and late toxicities were reported in 29 and 61% of patients, respectively. Severe grade 3 and 4 late complications were observed in nine patients but none of them led to mortality. **Conclusion:** Reirradiation appears to be both feasible and well tolerated in patients treated with previous radiotherapy for recurrent and second primary head and neck cancer. Careful case selection for reirradiation based on patient's performance status and tumor characteristics is essential.

### 2. Squamous Cell Carcinoma of the Superior Gingivobuccal Sulcus: An 11-year Institutional Experience of 203 Cases.

*Jpn J Clin Oncol. Sep 2014;44(9):807-11*

*Dewan AK, Dabas SK, Pradhan T, Mehta S, Dewan A, Sinha R*

**Objective:** The report presents an 11-year Institutional experience of 203 cases with superior gingivobuccal sulcus tumours receiving surgical intervention at a comprehensive tertiary cancer care centre. **Methods:** A retrospective chart review of patients with a confirmed diagnosis of squamous cell carcinoma of superior

gingivobuccal sulcus was done and data related to patient demographic profile, details of surgical procedure, follow-up and survival were collected. **Result:** Infratemporal fossa clearance was performed in 56 patients. The 10-year overall survival and disease-free survival was observed to be 39 and 52%, respectively, with a median follow-up of 15 months. The overall survival was 40 and 36%, respectively, in cases with and without infratemporal fossa clearance. Similarly, the disease-free survival was found to be 58 and 49%, respectively, in cases with and without infratemporal fossa clearance. **Conclusion:** Patients with higher stage tumours who underwent infratemporal fossa clearance showed better overall and disease-free survival than those who did not undergo infratemporal fossa clearance.

### 2. Transoral robotic surgery in management of oropharyngeal cancers: a preliminary experience at a tertiary cancer centre in India.

*Int J of Clinical Oncology, Dec 2014*

*Surender Dabas, Abhinav Dewan, Reetesh Ranjan, Ajay Kumar Dewan, Anoop Puri, Swati H. Shah, Rupal Sinha*

**Aim:** The aim of this observational prospective study was to determine the technical feasibility, safety and adequacy of surgical margins for transoral robotic surgery (TORS) in oropharyngeal cancers. **Methods:** From March 2013 to May 2014, 60 patients with oropharyngeal lesions underwent TORS with or without neck dissection using the 'DaVinci' robot. Patients were observed and data recorded on surgical time, blood loss, complications and functional outcome. **Results:** All 60 patients underwent TORS, with neck dissection performed in 45 of them. A positive margin was seen in two patients (3.3%). Intent to treatment was radical in 42 patients and salvage in 18 patients. None of the patients required tracheostomy, and one patient (1.66%) died post-operatively. Post-operative complications in the form of primary haemorrhage required active intervention in three patients. Average estimated blood loss was  $26.5 \pm 31.1$  ml. Post-operatively, all patients had adequate swallowing and speech function with nasal twang reported in three patients on long-term follow up. Patients started tolerating oral feeds within a week of procedure (mean 3.96 days), with the nasogastric tube removed on the ninth postoperative day (mean 9.19 days). No long-term gastrostomy tube dependency was reported. **Conclusion:** TORS is a safe, feasible, minimally invasive procedure in patients with oropharyngeal cancers. It has the least morbidity and offers benefits in terms of avoidance of tracheostomy tube, prolonged Ryle's tube and gastrostomy dependency.

# 14th Annual International Conference **RGCON** 2015



## Changing Landscapes in **HEAD & NECK ONCOLOGY** Future & Beyond

### Live Workshop

- Robotic Surgery
- Brachytherapy

**February 27<sup>th</sup> - March 01<sup>st</sup> 2015**

Hotel Crowne Plaza, Rohini, Delhi, India

#### EMINENT FACULTY

Dr. Gregory Weinstein | Dr. Chris Holsinger | Dr. Yoon Woo Koh | Dr. Sat Parmar | Dr. Vincent Gregoire | Dr. Cai Grau | Dr. Eugen Hug | Dr. Chao Li

#### WHO SHOULD ATTEND?

Medical Oncologists, Surgical Oncologists, Radiation Oncologists, ENT Surgeons, Dental Surgeons, General Surgeons, Radiologists, Pathologists, Nuclear Medicine Specialists, and Post-Graduates in Concerned Specialities

#### Highlights of the Conference

Live Workshops, Panel Discussions, Masterclass - Case Capsules, Debates in Clinical Practice, Quiz & Abstracts

**Last Date for Abstract Submission : February 15<sup>th</sup> 2015**

**First 25 Paper / abstract submissions shall receive complimentary registrations to RGCON 2015.**

Registration Charges: For Consultants -₹3000/-, For Post-Graduate & Trainees -₹1500/-  
International Delegates May Pay Delegate Fee in Equivalent of USD



**Rajiv Gandhi Cancer Institute  
and Research Centre**

A Unit of Indraprastha Cancer Society  
Registered under "Societies Registration Act 1860"

Accredited by :



For registrations & further details,  
Please contact:

**Department of Marketing**

rgcon2015@gmail.com

+91-11-4702 2157 / 2621

+91-8130245511

Sector-5, Rohini, Delhi-110 085, India, web: [www.rgcon.org](http://www.rgcon.org)