

Accredited by :



Rajiv Gandhi Cancer Institute  
and Research Centre

November 2015

# newsletter



Vol. XIX | No.11 | Price: 50 Paisa

## EDITORIAL

### BRAIN DRAIN

Brain drain has become a major concern of the developing countries especially India. This term emerged in 1960s when skilled workforce started migrating from poor countries to the rich countries in search of better job opportunities and living conditions. Top Indian professionals and entrepreneurs today in USA had actually left India in 70's and 80's for greener pastures due to political and economic systems.

We had rapidly growing population and thousands of doctors and engineers graduating out every year but no jobs were being generated. The entrepreneurs were also leaving the country to set up their business abroad. Our graduates had no choice but to look for greener pastures. Countries like US and UK were welcoming them with open arms. Our talented brains and entrepreneurs did not leave our country but our policies pushed them out. It drained them out. Our talents raised slogan "Brain drain is better than a brain in a drain."

Now the trend is slightly different, the students try their luck for higher studies abroad and they have an edge over the students from other countries in terms of skills and knowledge. IIM-B (Indian Institute of Management – Bangalore) in a recent study has shown that number of students going abroad has increased by 256% in last 10 years. India has failed miserably in attracting the best brains. We often talk of shortage of skilled manpower especially in medical field. Problem is not that we don't produce but we don't retain.

The western world says "You take the reserved, we will take your deserved."

Most of the students prefer staying back in the host country due to better work opportunities and heavy pay packages. After getting good global exposure and experiencing good quality of life, students become reluctant to come back to their home country.

Wake up call for India!

After witnessing a huge brain drain of doctors (among the 3,000 medical students went abroad in last three years, none returned), the health ministry has suspended issuing "no obligation to return certificates" to the medical students going abroad for higher studies. Further, the medical students going to the US for higher studies now have to sign a bond with the government, promising to return to India after completing his / her studies. If the student doesn't fulfill the bond obligation, the ministry can write to US and the permission for the student to practice in the country may be denied. While India is putting the best foot forward to curb brain drain, there are signs of reverse brain drain where a few best brains are returning to India. With better economic policies, there is still hope for India.

Reverse brain drain is a form of brain drain where human capital moves in reverse from a more developed country to a less developed country. These migrants may accumulate savings, also known as remittances, and develop skills overseas that can be used in their home country.

India should embrace their returning intelligentsia with favourable migration policies to attract foreign academics and professionals. India needs to develop an environment which will provide rewarding opportunities for those who have attained the knowledge and skills from overseas.

Let us retain the deserved

Let us reverse the flow of brain drain by providing right opportunities to the academia.

**Dr. A. K. Dewan**  
Medical Director





## INAPPROPRIATE LUMPECTOMY CHALLENGES AND STANDARD OF CARE IN EARLY BREAST CANCER

The incidence of breast cancer has enormously increased over the past few decades. As of today breast cancer affects one in twenty five to thirty women in India. However increased awareness and imaging has helped in early detection and prompt treatment atleast in the urban population. About more than half of the women presenting at our institute have early breast cancer. A disturbing trend in the present setting is that a substantial proportion (around 10 %) of patients are referred for the management of early breast cancer after inappropriate excision as diagnostic procedure in the primary care setups general surgeons.

### Issues In Management of Carcinoma Breast Post Lumpectomy



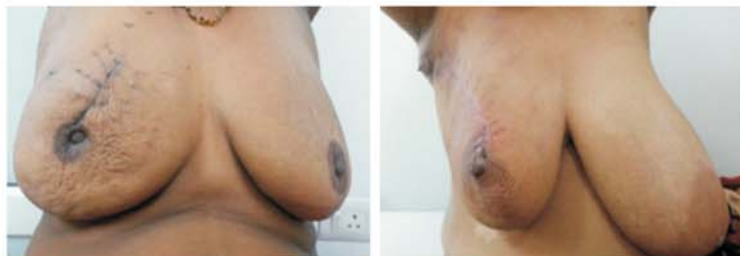- INAPPROPRIATE INCISIONS
- UNKNOWN MARGINS

- IMAGING FOR RESIDUAL DISEASE
- NO ACCURATE T STATUS

- REVISION SURGERY
- ADJUVANT THERAPY

### Inappropriate Incisions:

One of the major confounding factors is such a situation are inappropriate incisions. The incisions have to be planned so that they lie within the definitive surgical incision if revision is required. Oblique incisions, ugly scars, post excision in duration, drains, periareolar incisions mar the prospect of future conservation of the breasts and warrant mastectomy and is unacceptable for all standards in 2015.

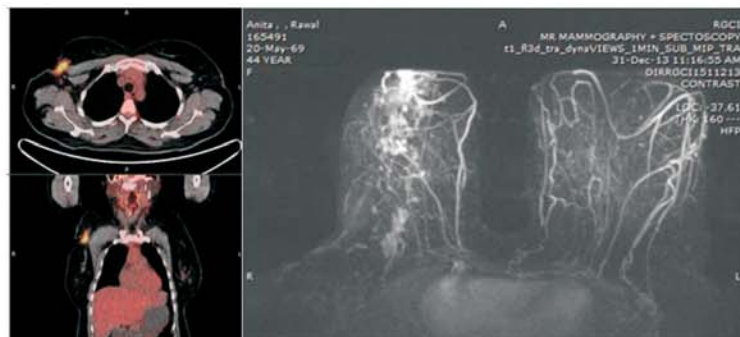

### Unknown Margins:

The second major problem of inappropriate excision is that margins are not known in 75 % of the cases. In a piece-meal excision margins cannot be determined. A wide local en bloc excision is always preferred without drains. Unknown margins again warrant revision surgery.

### Imaging for Residual Disease:

The second major problem of inappropriate excision is that margins are not known in 75 % of the cases. In a piece-meal excision margins cannot be determined. A wide local en bloc excision is always preferred without drains. Unknown margins again warrant revision surgery.



Pet CT & MR Mammogram Helps Assess Residual Disease.

### No Accurate T Status:

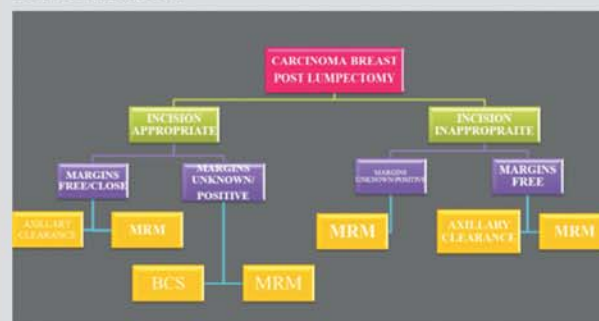
The most important information i.e. the size of the tumor is not known especially if the tumor was excised piece meal. So an accurate T staging is not possible. An accurate T staging is essential for deciding adjuvant chemo and radiotherapy. The T status is also a prognostic factor and stratifies outcome. The T status is thus lost forever.

### Revision Surgery:

All cases of post lumpectomy require revision surgery for breast cancer. But if the margins are known and free then just axillary clearance /SLNB will suffice. If the margins are involved then either modified radical mastectomy or re-excision of lumpectomy cavity with axillary clearance can be done. Wider excisions are required and hence major reconstructions in case of breast conservation.

### Decision on Adjuvant Therapy:

Because accurate T staging is not available deciding adjuvant therapy is challenging. You either end up overtreating or undertreating with either chemotherapy and or radiation.



Surgical Management Of Carcinoma Breast Post Lumpectomy

### Triple Assessment is the Gold Standard

Triple assessment of breast lump with appropriate imaging, clinical examination and trucut biopsy is the gold standard in the management of breast lumps. All breast lumps are not cancerous but require triple assessment to avoid inappropriate excision in the setting of breast cancer.

### Conclusion:

In early breast cancer, inappropriate lumpectomy for diagnostic purpose alters the course of surgical and adjuvant management. Hence it should be discouraged and not advocated as standard of care.

**Dr. Rajeev Kumar**, Sr. Consultant & Chief of Breast Surgical Oncology  
**Dr. S. Veda Padma Priya**, Consultant – Breast Surgical Oncology





## MICROVASCULAR FREE FLAP RECONSTRUCTION FOR HEAD AND NECK CANCERS

Reconstruction with free flaps has significantly changed the outcome of patients with head and neck cancers. Availability of infrastructure, selection of the case, choice of flap, estimation of cost and complications associated with treatment should be evaluated prior to procedure.

**The vast majority of malignant tumors of the head and neck are squamous cell carcinomas**, heterogenous in behavior, arising from the mucosal lining of the upper aero-digestive tract. Because of the accessibility of the oral cavity, and the morbidity of radiation-induced xerostomia, early tumors of this area (T1 and T2) are generally treated surgically. Locally advanced lesions (T3 and T4) are typically treated with combination therapy.

Resection of **buccal mucosa** malignant lesions may result in large, full-thickness soft-tissue (may involve bone), which may include skin also, with significant cosmetic consequences. Options for reconstructions include skin graft, local flaps like buccal mucosal/tongue/palatal flaps, pedicle flaps like temporalis, forehead, pectoralis major myocutaneous flap, deltopectoral flaps and free tissue reconstruction which is preferred.

Smaller resections of **tongue** are treated with primary closure or skin-grafting, whereas larger defects generally require free tissue transfer (free radial artery forearm flap which may be sensate) to maintain tongue mobility and optimize oral function.

Most **maxilla** defects result from the surgical ablation of maxillary tumors or tumors arising from adjacent structures, including the paranasal sinuses, palate, nasal cavity, orbital contents, overlying skin, and intraoral cavity. Primary goal of reconstruction is to maintain the ocular globe position and function, and/or fill the orbital cavity following orbital exenteration; reconstruct the intraoral, cheek, palatal, and nasal lining to restore speech, mastication, and oral continence; restore external skin and three-dimensional facial contour. Traditionally, prosthetic appliances were used along with split thickness skin grafting to line the defect cavity to prevent contractures, is still a reasonable option in some patients. This method of reconstruction relies on adequate support from the remaining tissues. But leakage and oronasal regurgitation because of bulky dentures, inadequate dentition, and poor retentive surfaces, the need for cleaning, and repeated prosthetic refinements are common problems.

Another method of reconstruction is use of autogenous tissues. Small defects of the maxilla can be primarily reconstructed with local soft-tissue flaps with or without supplemental bone grafting. In the past larger defects were repaired with a variety of pedicled flaps including the deltopectoral, pectoralis major, latissimus dorsi, temporalis, sternomastoid, and trapezius myocutaneous flaps. These flaps were limited by the length of vascular pedicle, inadequate tissue to fill the defect, or required multiple stages to achieve a final result.

More recently, microvascular free tissue transfer has significantly expanded the reconstructive surgeon's armamentarium for maxillary reconstruction. There are many different composite flaps that can be transferred to the midface without limitations of vascular pedicle length or flap geometry, including fibula, scapula, and iliac crest flap. The two flaps most commonly used that have large and long pedicles are the rectus abdominis myocutaneous and radial forearm flaps. Large surface area and small- to medium-volume defects are best reconstructed with radial forearm fasciocutaneous or osteocutaneous flaps. Large-volume and medium- to large-surface area defects are best reconstructed with rectus abdominis free flaps. Bone reconstruction is best accomplished with bone grafts for the floor of the orbit and vascularized bone flap for the maxillary arch. Critical midfacial structures, such as the lips, eyelids, and nose, should be addressed separately, using local flaps if possible. The majority of patients whose maxillary defects are reconstructed by using free tissue transfers have remarkably good function.

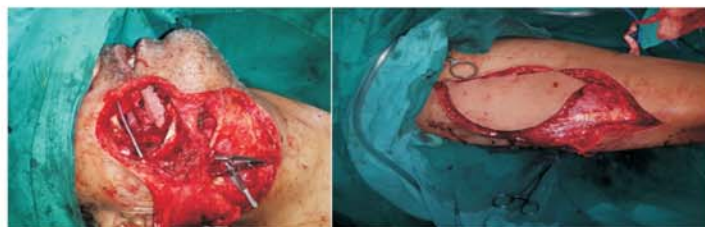**Mandible** reconstruction can be accomplished by a variety of means. Nonvascularized bone grafts for a short bone gap (upto 3 cm and candidates who have not received and will not receive radiation). The success rate in mandibular reconstruction with nonvascularized bone graft is about 70%.

Pedicled flaps include the trapezius and pectoralis osteomyocutaneous flaps. These flaps generally are not recommended as a primary method of mandible reconstruction. Perhaps the greatest limitation of these flaps is that they do not provide enough tissue in the proper configuration to be useful.

Prosthetic mandible replacement has evolved as an alternative method of reconstruction which includes metal reconstruction plates available today in a variety of lengths and styles. Metal reconstruction plates offer advantages of decreased operating time and avoidance of a bone graft donor site. They have important disadvantages: risk of exposure or infection; risk of plate fracture; preclusion of dental reconstruction; and a thin shape that does not provide adequate bulk for reconstruction and the functional limitation for hemimandible defects that include the condyle; as occlusion is often poorly maintained with a metal plate that includes a condyle. The pectoralis major myocutaneous flap is commonly used to provide soft-tissue coverage. One in three plate reconstructions fail when a pedicled flap is used for coverage.

The most reliable soft-tissue coverage for a reconstruction plate is provided by a free flap, which provides abundant tissue and can be inset without tension. Free flap survival rates are approximately 95%. The radius, the scapula, and the ilium (to a diminishing extent) are better choices in a few specific setting but the fibula is currently the donor site of choice for most patients. The bone is available with enough length to reconstruct any mandible defect. The straight quality of the bone with adequate height and thickness constitutes the ideal bone stock for precisely shaping a mandible graft. This method also provide better cosmetic results.

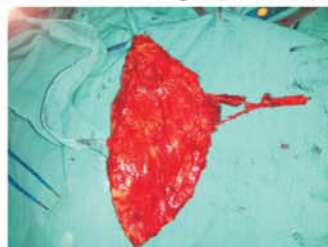




Defect After Tumor excision

Donor area for ALT flap RT Thigh

We have performed 103 free flaps for reconstruction of the head and neck in seven months period from April to November. Radial forearm free flaps (RFF, 49) and anterolateral thigh (ALT, 29)

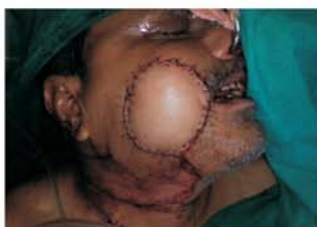

Free ALT flap with its feeding vessels

flaps and Free fibula (FF, 25) were the 1.75 most commonly used free flaps. RFF was the choice of flap in defects of the tongue (17 cases), rest of the cases had buccal myomucosal defects were reconstructed by RFF flaps & ALT flaps. 25 cases involving complex defects of the buccal mucosa with segmental

mandibulectomy and soft tissue defect (buccal mucosa/skin cover), were reconstructed with free fibula flaps. One case of resected anterior segment of the mandible with lower lip loss was reconstructed using free fibula osteocutaneous flap. 1 RFF & 1 ALT was done for neopharynx reconstruction after total laryngectomy. In 2 patients double free flaps were performed where defect was large & involving mucosa, cheek skin and mandible.

Complications, flap loss were seen in 7 (6.7%) cases with re-exploration done in all cases, suggestive of venous thrombosis. Local flaps, nasolabial (1) and



After inset of free ALT flap

PMMC flap (2) were done as 2nd option. Two cases of donor site morbidity with pain and stiffness in wrist were reported.

The technique of reconstruction with microvascular free flaps increased the options for not only to cover but to reconstruct larger defects with improved functional and cosmetic outcomes. This procedure demands dedication, patience, sincerity and hard work.

This is limited not only to the surgeon but also involves the anaesthetist and nursing staff. The commitment and dedication of the entire unit is the single most important factor for the success of any microsurgery.

**Dr. Rajan Arora**, Sr. Consultant – Reconstructive & Micro Vascular Surgeon

**Dr. Rahul Kapoor**, Consultant – Reconstructive & Micro Vascular Surgeon

**Dr. K. S. Mishra**, Attending Consultant

*In  
fond  
remembrance....*



**ACM OP Mehra, PVSM**

"Your life was a blessing, your memory a treasure; you will be loved beyond words and missed beyond measure."

Management of RGCIRC condoled the passing away of ACM OP Mehra, PVSM, a Founder Member of the Institute, on November 8, 2015. His contribution to the growth of RGCIRC, as its founder member was immense and will be remembered forever. His life was a symbol of dedication and leadership. He was a man of impeccable integrity with singular faith in social services.

He served as the Chief of Indian Air Force (1973 – 76) and was honored with Param Vishishth Seva Medal (1968) & Padam Vibhushan (1977). He served as the Governor of Maharashtra (1980 – 82) and Rajasthan (1982 – 85). He always preached, "We owe a certain obligation to our society and to our own spiritual being. Selfless service always opens up new avenues for the soul's expression".

Mr. D. S. Negi (C.E.O.)  
Dr. A. K. Chaturvedi  
Dr. D. C. Doval  
Dr. Gauri Kapoor  
Dr. Anurag Mehta  
Dr. S. A. Rao  
Dr. P. S. Choudhury  
Dr. S. K. Rawal  
Dr. Dinesh Bhurani  
Dr. Sunil Kr. Gupta  
Dr. B. K. Naithani  
Dr. (Col.) A. K. Bhargava  
Dr. Vineet Talwar  
Dr. Sheh Rawat  
Dr. S. K. Sharma  
Dr. Shivendra Singh  
Dr. Rajeev Kumar  
Dr. Rajan Arora  
Dr. R. S. Jaggi  
Dr. L. M. Darlong  
Dr. Swarupa Mitra  
Dr. Ullas Batra  
Dr. Sanjeev Gupta

Architect's Impression of RGCIRC (post expansion)



Printed & Published by Mr. K. K. Mehta on behalf of Indraprastha Cancer Society & Research Centre and Printed at Raju Art Printers, 18-A, Old Gobind Pura Extn., Street No. 2, Parwana Road, Delhi-51, Tel. : 9871006333, Published from RGCIRC, Sector-V, Rohini, Delhi-110085

To:

---

---

---

---

---

*If undelivered please return to :*

Rajiv Gandhi Cancer Institute & Research Centre  
Sector-V, Rohini, Delhi-110085

Editor : **Dr. A. K. DEWAN**

[www.rgcirc.org](http://www.rgcirc.org)