



Newsletter

Vol. XXI | NO. 8 | Price: 50 Paisa

EDITORIAL

Doctor - Patient Relationship (Communicate more without words)

The relationship between a doctor and his patient is one of the most sensitive associations. Successful professionals understand the importance of communication through body language. On the other hand, less successful professionals seem unable to send the simple signals that build good rapport.

We as professionals, may speak volumes to one another without necessarily uttering a word. A doctor should also be aware of the non-verbal messages that people are sending to him. You should fully appreciate the impact that your own body language is having on others. Look at yourself in a mirror. Do you sit in a way that expresses defensiveness or anger or does your position convey a friendly, open attitude? By using your own non-verbal language effectively, you can improve all your relationships and bring out the best in your patient and his family members.

When a patient seeks professional help from someone new, it is possible that he is unaware about the individual's skills. It is also possible that he may distrust simple advice because he may firmly believe that his situation is unique. To further complicate the relationship, he may like to hear only what he wants to hear and be unprepared to receive any negative comments from the professional. All these factors can make the professional's role treacherous.

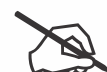How can you build a constructive relationship? One way in which the doctor can create a feeling of security on the part of the patient is to take notes on what the patient is saying. This will make the patient feel that his unique situation is being recognized and noted. The doctor can make the patient feel, he is paying attention by using positive gestures. For

instance, he can lean slightly forward with his head tilted to one side, perhaps supporting his head on one hand. The non-verbal communication should indicate that the patient's words are of great interest and doctor is thinking of ways to help the patient. It is equally important to avoid using negative gestures e.g., steepling gestures and attending to multiple phone calls during discussion with patient. That is why it is increasingly common for professionals and clients to meet on common ground such as a conference table. A doctor must communicate that he is an expert without seeming arrogant and should not imply that the patient is less intelligent than he is.

A doctor should also observe patient's body language. If you feel that he is communicating doubts or unease, reassure him using both words and your own positive body language. If you are successful, you will soon see gestures indicating that your patient is more relaxed and receptive to your professional advice.

Positive gestures of a doctor include open, relaxed attitude, taking notes, making eye contact and listening to patient without interruptions like phone calls. Signs that a patient is doubtful or worried are indicated by tense, closed position with closed legs, clenched hands, turning away from doctor and rubbing on face or eyes in doubt.

There is much more to a person than what he says with words, and sometimes even more than he shows through his facial expressions. This insight alone will make you more aware of everyone around you, which, in turn, will make others feel more appreciated and better understood. The result will be more effective if you have positive non-verbal communication with your patient.



Dr. A. K. Dewan
Director – Surgical Oncology

Challenges in Limb Salvage Surgeries - After Previous Inappropriate Surgery

Limb salvage surgeries are currently the norm for the management of bone and soft tissue tumors.

We, as Musculoskeletal tumor surgeons, face the following challenges in a successful limb salvage for a patient with these tumors.

1. Challenges dictated by the tumor itself like involvement of surrounding muscles, neighboring joint or a major motor nerve.
2. Some challenges are faced in view of particular age group like expecting a significant limb length discrepancy or in view of socio-economic conditions.
3. But still a previous inappropriate/inadequate surgery remains one of the most important preventable challenge faced in our scenario.

An inappropriate surgery poses a notable issue as it can lead to change in the reconstruction plan, higher need for flaps for wound cover, significant increase in the cost of treatment and sometimes precluding the chances of successful limb salvage surgeries.

In this paper, I highlight the challenges faced by MSK tumor surgeons due to previous inadequate and inappropriate surgeries.

First case, a 30 year old male patient presented to us with a residual soft tissue sarcoma of proximal leg medial aspect, with involvement of the underlying tibia with local infection (Fig 1). He was operated a month back outside without a biopsy or local imaging. His biopsy report showed clear cell sarcoma with intralesional margins. His MRI showed a residual disease with involvement of underlying tibia (Fig 2). He also had a persistent pus discharge and non-healing wound.

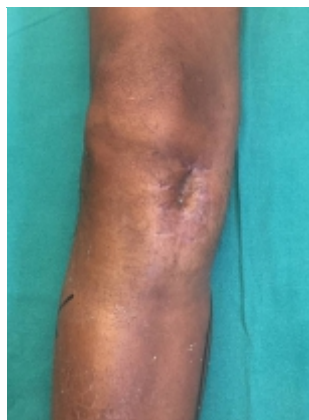

Fig 1

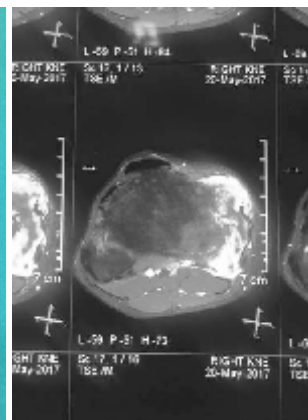


Fig 2a

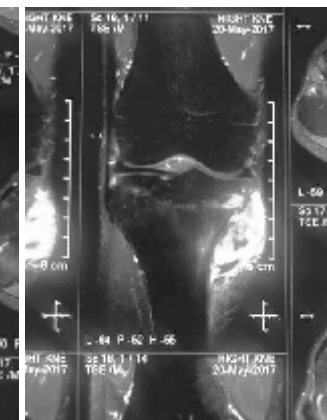


Fig 2b

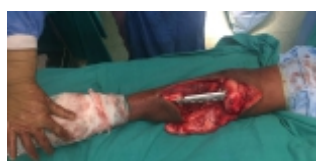

Fig 3a

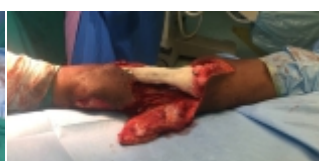

Fig 3b

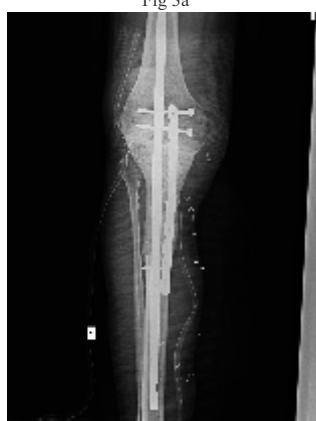

Fig 4a

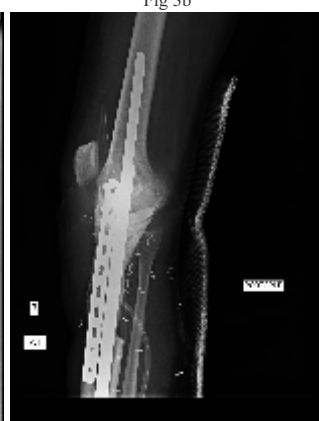

Fig 4b

His staging investigations showed a localized disease and histopathology review at RGCIRC confirmed the diagnosis of clear cell sarcoma. As it is a relatively chemo and radio resistant tumor, surgery is the primary mode of management.

Now, in this case a complete excision of the tumor was possible only with an excision of underlying bone and the scar. A limb salvage was technically challenging due to persistent infection which precluded the use of mega prosthesis. Also, in view of need for adjuvant radiation therapy, a flap cover was also required. So, the patient was advised for proximal tibial excision with wide excision of the lesion with primary nail cement spacer (with antibiotic cement) and a flap cover. The other option was an above knee amputation, for which the patient was not willing.

He underwent proximal tibial excision with wide excision of the tumor. The defect was reconstructed with a nail-plate-cement spacer containing high dose antibiotics (Fig 3 & 4). The wound cover required a rotation flap done by the plastic surgery team (Fig 5).

His post-operative period was uneventful and he started full weight bearing walking from day 14 after wound healing. His final report showed clear cell sarcoma with clear margins. He is currently on adjuvant radiation therapy.

This case emphasizes upon the impact of previous inappropriate surgery on the final treatment plan. A mobile knee joint reconstruction without a flap cover would have been possible otherwise. This would have resulted in much better function and in a lesser cost.

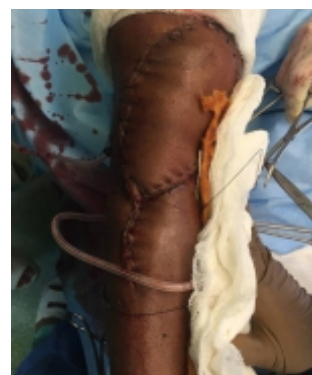

Fig 5a

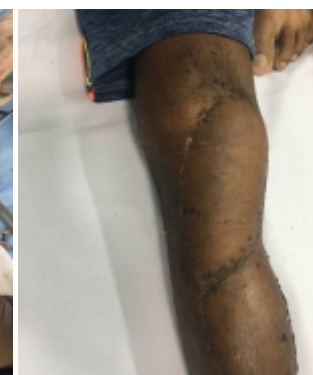

Fig 5b

Another gentleman, 62-year-old was not so lucky to get a limb salvage surgery after an inappropriate surgery. He had a right distal forearm soft tissue tumor for 4 months. He was right hand dominant. An MRI was done which showed a tumor close to ulna and interosseous space. Unfortunately, for him that general orthopedic surgeons and FNAC initially evaluated him was done which showed a spindle cell lesion? Benign and he underwent an excision of the lesion using two incisions (1 on volar aspect and other on dorsal aspect) (Fig 6).

Final report showed a Biphasic Synovial sarcoma and as expected, the margins were intralesional. Then the patient presented to RGCIRC for an opinion. His slide review showed Synovial sarcoma and staging work up showed non-metastatic disease. His MRI showed residual disease.

As all the planes in the lower forearm were contaminated due to previous intralesional surgery, the only option to get wide margins was a below elbow amputation. He underwent the same and is currently on adjuvant chemotherapy.

Through these cases, I want to highlight the following things -

1. FNAC, although very commonly used, has no role in primary evaluation of bone and soft tissue tumors.
2. Aim of Limb salvage surgeries in any bone/soft tissue sarcoma is to get wide margins. This might not be possible after inappropriate or inadequate surgeries. Many of the times, I as a surgeon, need to do an ablative surgery for achieving this goal.
3. I therefore request all my colleagues to get the evaluation and treatment of suspected bone and soft tissue sarcomas in a specific sarcoma centres to avoid preventable challenges.

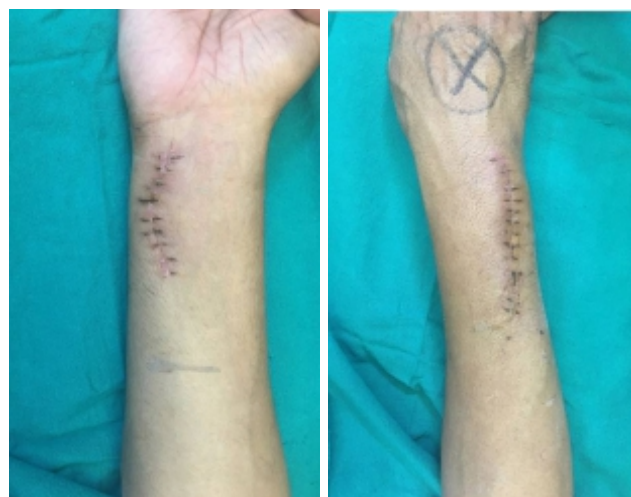

Fig 6a

Fig 6b

Dr. Manish Pruthi, Consultant - Orthopedics Surgical Oncology

Dr. Rajan Arora, Sr. Consultant - Cosmetic, Plastic and Reconstructive Surgery

CME on Medicine or Legal Medicine? Medico Legal Practices for Healthcare Providers

RGCIRC organized CME on Medicine or Legal Medicine? Medico Legal Practices for Healthcare Providers on Saturday, 5th August, 2017, at Hotel Crowne Plaza, Rohini, Delhi. Dr. D. C. Doval, Director - Medical Oncology delivered the opening remarks and Dr. Purvish M. Parikh, Director of Precision Oncology, Asian Institute of Oncology, Somaiya Hospital, Mumbai delivered Primary Talk in the said CME. The CME also had a panel discussion on Medicine or Legal Medicine Issues, which was moderated by Dr. Vineet Talwar, Co-Director - Medical Oncology. The panelists of this session were Dr. Purvish M. Parikh, Dr. Girish Tyagi, Registrar - Delhi Medical Council, Mr. D. K. Sharma, Lawyer - Delhi High Court, Dr. R. K. Gupta, Past President, DMA, Dr. A. K. Dewan, Director - Surgical Oncology, Dr. Anurag

Mehta, Director - Lab, Molecular Diagnostics and Research, Dr. P. S. Choudhury, Director - Nuclear Medicine and Ms. Mansi Bajaj, Legal Consultant. All the burning aspects regarding medical and legal issues were extensively deliberated upon with active participation in open house discussion by over 100 participants. The CME was very well appreciated by the gathering.



Delhi Breast Oncology Group Meet



RGCIRC organized monthly meeting of Delhi Breast Oncology Group on Hereditary Breast Cancer: Clinical Implications on Saturday, 12th August, 2017, at Hotel Crowne Plaza, Rohini, Delhi. Dr. A. K. Dewan, Director - Surgical Oncology delivered Welcome Address and Dr. Rajeev Kumar, Sr. Consultant - Surgical Oncology delivered a lecture on Hereditary Breast Cancer - An Overview. The CME also had scientific lectures on 'Who Should be Tested', 'Genetic Counseling' and 'What & How - BRCA & Beyond' along with a panel discussion. Various oncologists from Delhi NCR participated in the CME.

Date of Printing: 25th August 2017

Date of Publishing: 30th August 2017

Posted at: Ashok Vihar, Head Post Office, Delhi - 110052

Registered with Register of Newspaper Under No.68797/98

Postal Department Registration No. DL(N)/004/2015-17

Licensed to Post without Prepayment Under No.: "U"(DN)-162/2015-17



**Rajiv Gandhi Cancer Institute
and Research Centre**

A Unit of Indraprastha Cancer Society
Registered under "Societies Registration Act 1860"

The management would like to thank all the patients
and care givers for reposing confidence in RGCIRC



**Rajiv Gandhi Cancer Institute
and Research Centre
has once again been rated as
The Best Cancer Care Hospital in India**

at the

National Business Leadership &
Service Excellence Awards, 2017

Mr. D. S. Negi (C.E.O)
Dr. S. K. Rawal
Dr. A. K. Chaturvedi
Dr. D. C. Doval
Dr. Gauri Kapoor
Dr. Anurag Mehta
Dr. (Col) A. K. Bhargava
Dr. S. A. Rao
Dr. P. S. Chaudhary
Dr. Dinesh Bhurani
Dr. Munish Gairola
Dr. Vineet Talwar
Dr. Rupinder Sekhon
Dr. Shivendra Singh
Dr. Rajeev Kumar
Dr. Kundan Singh Chufal
Dr. Swarupa Mitra
Dr. Sumit Goyal
Dr. Ullas Batra
Dr. Rajan Arora
Dr. R. S. Jaggi
Dr. L. M. Darlong
Dr. Lalit Sehgal
Dr. Manish Pruthi
Dr. Sunil Kr. Khetarpal



To:

If undelivered please return to:
Rajiv Gandhi Cancer Institute and
Research Centre, Sector - 5,
Rohini, Delhi - 110085

Printed and Published by Mr. K. K. Mehta on behalf of Indraprastha Cancer Society & Research Centre and printed at
Raju Art Printers, 18 - A, Old Gobind Pura Ext., Street No. 2, Parwana Road, Delhi - 110051, Tel: +91 - 8744820804,
Published from Rajiv Gandhi Cancer Institute & Research Centre, D - 18, Sector - 5, Rohini, Delhi - 110085

Editor: Dr. A. K. Dewan