

PATRONS

AVM H L Kapur
Shri B L Joshi

GOVERNING COUNCIL

Chairman: Dr K V Swaminathan
Vice Chairman: Smt Renu Karnad
Hony. Secretary: Smt Jyotsna Govil
Treasurer: Shri O P Nayar
Principal Advisor: Shri K K Mehta

Members

Shri Madan Agarwal
Shri R N Bansal
Smt Harmala Gupta
Shri Rakesh Chopra
Shri Pramod Maheshwari
Shri R K Ahooja
Representative of LG of Delhi

RESEARCH ADVISORY COMMITTEE

Dr K V Swaminathan
Dr S P Tripathy
Dr Ashok Mohan
Dr R A Badwe
Prof A B Dey
Dr K Satyanarayana
Dr Panna Choudhury
Dr M Siddiqui
Dr Prema Ramachandran
Dr N K Grover
Dr Tejinder Kataria
Dr A K Vaid
Shri D Ragavan
Dr G L Telang
Representative of DGAFMS
Representative of DGHS
Director ICPO
Dr D C Doval

RESEARCH & ANALYSIS TEAM

Editor : Dr D C Doval
Director Research

Ms Rupal Sinha *Research Officer*
Mr Saud Azam *Research Officer*
Mrs Swarnima Jaitley *Research Officer*
Dr (Mrs) Harsh Sachdeva *Research Officer*

Printed and Published by
Rajiv Gandhi Cancer Institute
and Research Centre, Sector - V
Rohini, Delhi - 110085

From the Desk of Director Research

You have the December 2009 issue of Cancer News in your hands which is the first version edited by me as Director Research. Cancer News is addressed to all doctors, scientists and students involved in the oncology field. I would like to express my sincere appreciation to my seniors, peers and colleagues from whom I have learnt a lot. I am thankful to all the members of the Governing Council for putting their trust on me and giving me the opportunity to provide the academic feast in addition to the clinical services.

Imaging plays an important role in brachytherapy. 'Image Guided Adaptive Brachytherapy for Carcinoma Cervix: Current Clinical Perspective', covered under "Special Feature", is an emerging technique which provides major improvements in dose volume parameters and in clinical outcome.

MicroRNAs play a crucial role in cancer diagnosis, therapy and prevention. A special thanks to Dr Suresh Hedau, Scientist, Institute of Cytology & Preventive Oncology (ICMR), Noida, for reviewing the article on 'MicroRNAs in Cancer' which is highlighted under "Perspective".

A special gratitude to Ms. Jyotsna Govil, Hony. Additional Secretary, Indian Cancer Society, for providing valuable inputs in the article on "Cancer Awareness". Thanks are due to Dr. Maya Gottfried, Meir Medical Center in Kfar-Saba, Israel, for interactive discussions on lung cancer with Clinicians of the Institute. This has been highlighted under "Activities of RGCI&RC".

We also gratefully acknowledge the contributions made by the Clinicians, Scientists and DNB candidates of the Institute. Views and suggestions from readers on the Cancer News are welcome.

Wishing our readers a Happy, Prosperous and Healthy New Year 2010.

Dr. D. C. Doval

CONTENTS

- **Special Feature:** Image Guided Adaptive Brachytherapy for Carcinoma Cervix: Current Clinical Perspective [P 3 - 5]
- **Perspective:** Micro RNAs in Cancer [P 6 - 7]
- **Cancer Awareness:** You are Always the First to Know [P 8 - 9]
- **Research & Development:** Complete Human Epigenome Mapped; Maternal-fetal Transmission of Cancer; Molecular Flag for Prostate Cancer; Promising New Molecular Strategies [P 10]
- **New Technologies: New Drugs -** Bayer's Novel Anti-Cancer Compound; Folutyn for Peripheral T-Cell Lymphoma; New Kidney Cancer Drug; Targeted Genetic Medicine **Diagnosics-** LightTouch Technology; Response DX: Gastric Tests **Techniques-** Minimally Invasive Device; New Vista for Cancer Surgery [P 11 - 12]
- **Breast Cancer:** Breast Cancer Symposium; BREVAGENTM Test; Lymphedema; Stem Cell from Menstrual Blood [P 13]
- **Clinical Trials:** Erbitux for Advanced Colorectal Cancer; Follicular Lymphoma; New Standard Treatment Option; Ovarian Cancer [P 14]
- **Watch-Out:** Breast Cancer Screening; Immune Response to PSA; Prevention of Epithelial Cancer; Taxane Compounds [P 15]
- **Globe Scan:** New Field of Research; DNA of Breast Cancer; Parasite Growth Hormone & Cancer; Reduce Tobacco Use [P 16]
- **Activities of RGCI&RC:** Case Discussion: Lung Cancer [P 17]
- **Case Reports from RGCI&RC:** Anorectal Melanoma; Gastric Tuberculosis [P 18 - 19]

This publication aims at disseminating information on pertinent developments in its specific field of coverage. The information published does not, therefore, imply endorsement of any product/process/producer or technology by RGCI&RC.

Printed at
Sagar Printers &
Publishers,
1880 Udaichand Marg,
Kotla Mubarakpur,
New Delhi - 110 003.

SPECIAL FEATURE

IMAGE GUIDED ADAPTIVE BRACHYTHERAPY FOR CARCINOMA CERVIX: CURRENT CLINICAL PERSPECTIVE

Introduction

The role of brachytherapy in the treatment of cervical cancer has increased worldwide since its introduction over 100 years ago and is now essential component in its treatment. The standard technique consists of standard doses prescribed to a fixed empirical point (which may not reflect dose to tumor) and the use of plain x-ray imaging for treatment planning. Increasingly, imaging is playing a major role in brachytherapy as an aid to decision making for the appropriate target location, guiding the placement of applicators in that location and for performing treatment plans that derive the optimal radiation prescription "as conformal as possible to the target". During the last few years, three dimensional image based treatment planning in cervical cancer brachytherapy has been in vogue. Translating 3D concepts into clinical practice of brachytherapy requires knowledge of several complex steps: anatomy, pathology, 3D imaging, physics, biology, clinical experience and systematic application of dose volume parameters in the clinical staging. In 2005, recommendations for 3D image based brachytherapy were published by Gynecological-European Group of Curietherapy & European Society for Therapeutic Radiology and Oncology (GYN-GEC-ESTRO) which have now become standard and are the major advancement for the harmonization of Image Guided Adaptive Brachytherapy (IGABT).

Impact of MRI

Magnetic resonance imaging (MRI) (T2 weighted) undoubtedly provides superior soft-tissue resolution and is one of the best imaging modality for depicting cervical tumor size and extent compared to ultrasound and computed tomography (CT) scans. The value of MRI in imaging gynecologic malignancies lies in its superior contrast resolution, which enables visualization of cervical tumor size and volume, distinction of tumor from normal uterus and cervix, and defining of parametrial and vaginal infiltration of disease. Multiplanar scanning capabilities, including coronal, sagittal as well as axial views, are helpful in assessing the relationship of the applicators to the internal anatomy. MRI needs to be performed with

image compatible applicators. Titanium applicators provide the optimum in both CT and MRI imaging modalities. Moreover, they are easily sterilized, are lightweight and have added benefit of a small diameter tandem for easy insertion.

Basic Principles Applying for IGABT

Inherent aim of brachytherapy imaging is to offer the same high quality image for all the elements: applicators, potential source position, gross tumor volume (GTV), clinical target volume (CTV) and adjacent organ at risk (OAR). Various imaging methods (CT, MRI, PET, USG) may be needed for 'fusion' during the process of treatment planning for better delineation of GTV and OAR.

Imaging also plays an important role at different steps within the treatment chain, such as pre-planning, during application, treatment planning and image assisted quality control of dose delivery. Most important is the 'contouring' requiring higher precision due to sharp fall off in all directions as compared to external beam RT (EBRT) contouring.

Gross Tumor Volume

As per GYN-GEC-ESTRO, gross tumor volume (GTV) is defined through imaging plus any clinically visualized or palpable tumor extensions. This volume is meant to include the entire determinable tumor (the primary tumor in the cervix and its extensions to the parametria as determined by MRI and the clinical examination). The GTV generally regresses as the treatment (EBRT and brachytherapy) progresses. Hence the European Working Group has defined the GTV at the time of diagnosis (before any treatment) as GTVD, whereas the GTV at the time of each brachytherapy treatment is termed GTVB1, GTVB2, and GTVB3 and so on.

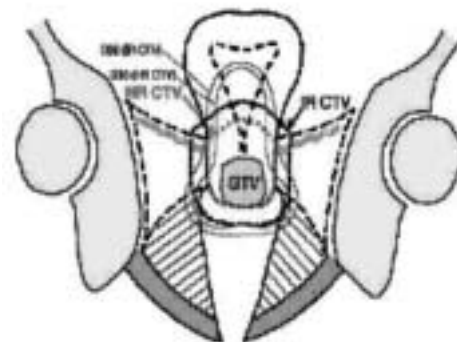


Fig 1: Diagrammatic representation of different target volumes at risk

Clinical Target Volume

There is a varying tumor load within the clinical target volume (CTV). Hence, three CTVs have been proposed according to tumor load and risk of recurrence as shown in Fig 1,2 and 3.

Adaptive brachytherapy takes into account the tumor size before starting EBRT and at every brachytherapy insertion with applicator in place. By use of response adapted CTV defined at the time of brachy therapy, it is possible to deliver much higher doses than currently possible.

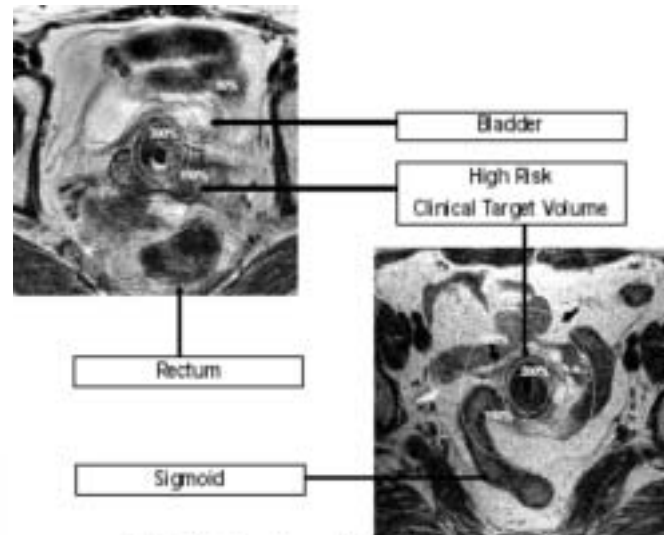
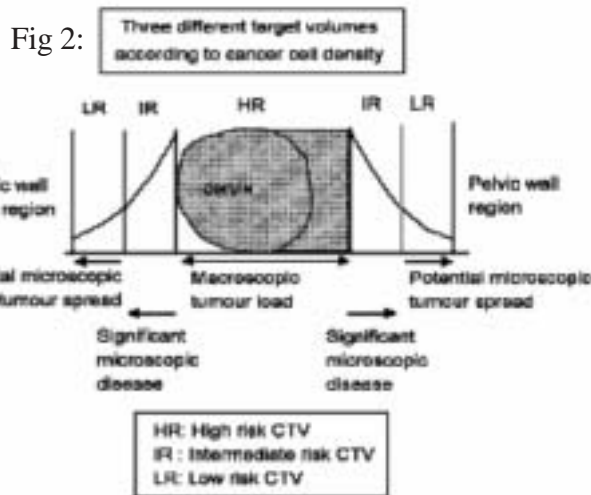


Fig 3: T2 FSE MR Axial sections showing HR-CTV and OARs

Variation (geographic/dosimetric) occurs between fractions within one application (intrafraction) or between different applications (interapplication). Intrafraction variations are difficult to define (like variations in positions of sigmoid and bladder) whereas interapplication variations are well documented and studied. Due to variation in tumor shape and size, applicator place, doses to OAR can vary substantially for different reasons. Hence, ‘adaptive treatment planning’ with MRI/ CT can define much better doses to GTV and at the same time reduce doses to OAR.

In brachytherapy setup, uncertainties (like in EBRT) cannot be compensated by adding margins. It is not possible to create a dose plateau in lateral and antero-posterior directions without causing dose escalation but maybe possible in longitudinal direction by loading the tandem above the target thereby manipulating doses towards uterine corpus and vagina.

Dose Prescription, Dose Volume Benefit from 3D Optimization

High risk CTV (HRCTV) dose is related to Point A dose distribution and should receive between 75-90Gy whereas the intermediate risk CTV (IRCTV) dose should be around 60 Gy which correlates to 60 Gy reference volume prescription used in Paris system. According to Potter et al, local control can exceed >95% (irrespective of tumor size and response) if target coverage (D_{90}) of HRCTV is 87 Gy or greater. This is exactly shown by Eifel et al that for orthogonal x-ray based brachy if point A dose is less than 85 Gy, 5-year pelvic disease recurrence doubles to 33% than those who received >85 Gy (16%). Hence, 87 Gy D_{90} for HRCTV can be taken as clinical cutoff value.

Organ-at-Risk

The definition of normal tissue volumes at risk (or organs-at-risk) should be prepared on the basis of MRI. For the imaging procedure, a magnetic resonance compatible treatment applicator must be in place along with a Foley’s catheter in the bladder. A rectal marker if used must be magnetic resonance compatible. The European group recommends contouring the organ (bladder or rectum) with its contents, whereas the American group advocates contouring only the organ wall. The dose to a representative portion of small bowel and sigmoid colon is to be estimated by contouring the intestines by using the outermost limit of all the intestines, rather than individual bowel loops within 5 cm from any brachytherapy source (Fig 3).

Uncertainties to be Dealt With

Reconstruction on CT of applicator is straight forward but MRI requires special reconstruction techniques. Use of marker tubes in source channel and co-registration between radiographs on CT and MRI are one of the ways to circumvent this problem.

The dose volume histogram (DVH) for each brachy fraction needs to be generated for each target volume (GTV, HRCTV and IRCTV) and OAR. Target related DVH includes the volume of target as well as D_{90} and D_{100} of the volume of interest. D_{100} has the practical limitation in accuracy as it is extremely dependent on target delineation and hence even a small spike (due to steep dose gradient) in contour can cause large deviations. D_{90} is less sensitive to these influences and is thus a more stable parameter. Also one should note the percentage of target volume receiving 100% of prescribed dose (V_{100}) as this describes how closely the intended treatment could be achieved in terms of target coverage, thus providing information indirectly on the proportion of the underdosed area. V_{150} , V_{200} are the volumes receiving at least 1.5-2 times the prescribed doses and their importance is that they indicate the relative amount of CTV in percent treated with significantly higher doses (50 or 100%) which is rather unique in radiation therapy.

Dose optimization by manipulation of dwell times and position is better possible in IGBT. For larger tumors the depth of prescription can be expanded typically by 5mm in intracavitary application. By addition of additional interstitial needles, parametrial involvement can be further targeted and it becomes possible to provide additional dose up to 15mm beyond point A without increasing dose to OAR significantly.

Non-optimized dose distribution in brachytherapy results in highly variable tumor doses. Lindegaard et al showed that with optimization non-homogeneous dose to target (D_{90} of CTV) can be made more homogeneous from 52-160% to 62-141%. And on top of this if adaptation is used in subsequent insertions, volume of HRCTV receiving more than 85 Gy can be doubled ($\alpha/\beta=10$). If HRCTV is < 40 cc, the dose to OAR is increased in typical 2D plan whereas it remains much less in IGBT cases. For HRCTV > 90 cc, extra interstitial needles may be required. 'Vienna' applicator (Fig 4) now has the provision to have interstitial needles along with intracavitary applicator.

Local recurrence within the true pelvis needs to be assessed and correlated with target related DVH parameter. Their topography needs to be correlated with high dose area of brachytherapy and HRCTV for possible geographical miss.

Dose Response Relationship for OAR

The main OAR in cervical cancer brachytherapy are rectum, bladder, vagina, sigmoid colon and relevant parts of bowel loops adjacent to target volumes. Due to proximity of these structures to target areas, often one has to do a balancing act by compromising dose to target in case of over dosage to OAR. In clinical practice dose to most critical tissue volume (D_{2cc}) is taken as a parameter for treatment plan optimization. For rectum D_{2cc} should be < 75 Gy [$\alpha/\beta=3$ (as per Vienna and Koom's study)] and similar constraints are extrapolated for sigmoid colon also. For bladder, it is < 90 Gy for D_{2cc} .



Fig 4: Vienna applicator

Future Perspectives

Data on IGBT lacks because of limited use in most of the institutes, but reports on clinical experience from different institutes validate the feasibility and potential of the procedure. The first available clinical results using MRI based approach show increased local control (in the range of 95-100%) in both limited and advanced disease and at the same time resulting in less than 5% severe late morbidity. Results of 'EMBRACE' study on MRI based IGABT to co-relate local control and late morbidity are anxiously awaited. As stated in review article by Takafumi Toita from Japan, reimbursement by insurance companies for IGABT will be another important factor for this high patient load disease which will go a long way to successfully implement this in larger clinical use by brachytherapists throughout the world.

(Dr Vivek Bansal, Senior Consultant, Dr Manjinder S Sidhu, Dr Preeti Bagga, Senior Residents, Dr Arpana Shukla, Additional Consultant, Dr Rajender Kumar, Dr Sajal Goel, Dr Sachin Kotur, DNB students, Dr Rakesh Agarwal, Consultant, Dept of Radiation Oncology, Dr Sudhir Rawal, Senior Consultant, Dr Rupinder Sekhon, Consultant, Dept of Surgical Oncology, Prof P S Negi, Chief Medical Physicist)

PERSPECTIVE

MICRORNAs IN CANCER

Introduction

MicroRNAs(miRNAs) are endogenous ~22 nucleotide RNAs, which can play important regulatory roles in animals and plants by pairing to the messenger RNAs(miRNAs) of target genes and specifying miRNA cleavage or repression of protein synthesis. The first miRNA was discovered in 1993 in the roundworm *C. elegans*. Since then, these short regulatory RNAs have been found to be an abundant class of RNAs in plant and DNA viruses and about 3% of human genes encode for miRNAs. miRNAs have been shown to regulate several genes known to play key roles in cancer. They can be involved in metastasis, invasion, proliferation, cell cycle and apoptosis and can function as either tumor suppressors or oncogenes.

Biogenesis and Function

In humans, miRNA genes are located on all chromosomes except Y chromosome. Primary miRNAs (pri-miRNA) are transcribed by RNA polymerase II from longer encoding DNA sequences which may be hundreds to thousands of nucleotides in length. In the nucleus, ribonuclease enzyme Droscha excises the pri-miRNA to form stem-like loop structures which are approximately 70 nucleotides long termed as precursor miRNA (pre-miRNA). After export into the cytoplasm, the pre-miRNA is cleaved by the ribonuclease Dicer to generate a short RNA duplex (miRNA: miRNA*). One strand of this duplex is the mature single-stranded miRNA which is incorporated into the RNA-induced silencing complex, while the complementary strand (miRNA*) is usually rapidly degraded. The miRNA incorporated into the silencing complex can bind to target messenger RNA by base pairing at its '3'-UTR, causing inhibition of protein translation and/or degradation of the target messenger RNA. In humans, miRNAs mainly inhibit protein translation of their target genes and only infrequently cause degradation or cleavage of the messenger RNA.

Detection Technologies

Some methods used to detect miRNAs and to determine miRNA profiles of particular cell types are:

- **Microarrays:** miRNA microarray is a high throughput approach to study the expression of miRNAs in cultured

cells or tissues. A set of oligonucleotide capture probes are spotted on glass slides and a sample of extracted RNA enriched for small molecule RNAs is allowed to hybridize with the capture probes. Many diseases which are associated with this have been discovered by this method.

- **Bead-Based Arrays:** Such as Luminex FlexmiR arrays, also permit simultaneous quantification of hundred of miRNAs.

- **Quantitative Real Time PCR:** Quantitative Real Time PCR can also be routinely used to detect miRNAs. Quantification of mature miRNAs usually requires reverse transcription of the miRNA with a stem-loop primer. DNA template is then used in the real-time PCR reaction.

- **Northern Blot Analysis:** Though it is a well established technique for studying miRNA expression, it has been adapted to detect miRNAs in cells and tissues.

- **In-situ Hybridization:** The detection of mature miRNAs has recently become possible by using special high affinity locked nucleic acid (LNA) modified DNA oligonucleotide probes and holds promise for the application on tumor formalin-fixed and paraffin embedded tissue.

Role in Cancer

The involvement of miRNAs in cancer is much more extensive than initially expected. Initial clues came from the observation that about 50% of known miRNA genes are located at sites of recurrent deletions or amplifications in human cancers (see Table).

Tumor Suppressing Activity: miRNAs with tumor suppressing activity include miR-15a and miR-16-1. The loss of their function in chronic lymphocytic leukemia and perhaps other cancers as well, may contribute to malignant transformation by up-regulating Bcl2, thereby preventing apoptosis. Hence, both miRNAs seem to act as tumor suppressors. miR-15a and miR-16-1 modulate the expression of other genes as well, some of which may also be relevant for cancer. Let-7 seems to operate as a tumor suppressor in lung cancer by regulating RAS oncogene. Whether colorectal, pancreatic and bladder cancers are elevated and activated by RAS levels and have also reduced let-7 levels, remains to be seen.

Oncogenic Potential: Some of the miRNAs with oncogenic potential include miR-372 and miR-373. Both are potential oncogenes that participate in development of human testicular germ cell tumors, which rarely display p53 loss of function and act by numbing p53 pathway, thus allowing tumourigenic growth in

Table: Cancer-Associated microRNAs and Their Potential Diagnostic Markers

| Cancer Type | Upregulated | Down-Regulated |
|-----------------------|---|--|
| Brain, GBM | miR-21, 221 | miR-128, 181 |
| Breast Cancer | miR-9-1, 10b, 17-5p, 21, 29b-2, 34, 146, 155, 181b-1, 213 | let-7, miR-15a, 16, 125a, 125b, 127, 145, 204 |
| Lung Cancer | miR-17-5p, 17-92, 21, 24-2, 106a, 128b, 146, 150, 155, 191, 192, 197, 199a-1, 203, 205, 210, 212, 214 | let-7, miR-9, 26a-1-p, 27b, 29b-2, 32, 33, 30a-5p, 95, 101-1, 124, 124a-3, 125a, 125a-p, 126, 140, 143, 145, 181c-p, 198, 192-p, 199b-p, 216-p, 218-2, 219-1, 220, 224 |
| Esophageal Cancer | miR-21, 93 | miR-203, 205 |
| Gastric Cancer | miR-21, 24-1, 24-2, 25, 92-2, 107, 191, 214, 221, 223 | let-7 |
| Colorectal Cancer | miR-17-5p, 20a, 21, 24-1, 24-2, 29b-2, 30c, 31, 32, 96, 106a, 107, 128b, 135b, 155, 183, 191, 221, 223 | let-7, miR-34, 127, 133b, 143, 145 |
| Hepatocellular Cancer | miR-15b, 18a, 21, 106b, 221, 222, 224 | let-7, miR-101, 122a, 125a, 195, 199a, 200a |
| Pancreatic Cancer | miR-17-5p, 20a, 20a, 21, 24-1, 24-2, 25, 29b-2, 30c, 32, 92-2, 100, 106a, 107, 125b, 128b, 146, 155, 181a, 181b-1, 191, 196a, 196b, 199a-1, 212, 214, 221, 223, 301, 376a | miR-139, 142-p, 345, 375 |
| Prostate Cancer | miR-17-5p, 20a, 21, 25, 30c, 32, 92-2, 106a, 146, 181b-1, 191, 199a-1, 214, 223 | miR-15a, 16, 143, 145, 218-2 |
| Cervical Cancer | miR-21, 199a | miR-143, 145 |
| CLL | miR-17-92, 155 | miR-15a, 16, 143, 145, 192, 213, 220 |

presence of wild type p53. miR-21 is found to be highly expressed in numerous cancers like breast cancer, glioblastoma and pancreatic cancer. Apparently, miR-21 functions as an oncogene by inhibiting pro-apoptotic genes. While both B-cell integration cluster and miR-155 were found to be highly expressed in Hodgkin's primary mediastinal and diffuse large B-cell lymphomas, Burkitt lymphoma and non-small cell lung cancer, a reduced expression was detected in pancreatic cancer. A cluster of miRNAs known as miR-17-92 which encodes six miRNAs (miR-17, miR-18a, miR-19a, miR-20a, miR-19b-1 & miR-92-1) transcribed together as one poly-cistronic transcript, act as oncogenes in numerous cancers.

Diagnosics: miRNA expression profiles can clearly differentiate human cancers according to their developmental origin. It is suggested that detection of cancer-associated specific miRNAs in each malignant tumor from tissue sample and/or serum will contribute to early detection and accurate diagnosis of cancer. One advantage of miRNAs over mRNAs in pathological diagnosis is their high stability, i.e., miRNAs are long lived in vivo and very stable in vitro which might allow the analysis of paraffin-embedded samples.

Cancer Classification & Prognosis: Findings suggest that miRNA profiling is more informative than regular mRNA profiling. Prognostic miRNA expression signatures may be identified within tumor groups that predict, eg, high progression risk, poor survival or presence of metastases indicating for closer monitoring and adjuvant therapy.

Therapy: At present, there are no reports of the use of miRNAs for in vivo anti-cancer therapy. However, the development of approaches for in vivo delivery of short interfering RNA and short heteroduplex RNA in preclinical models have used viral vectors, liposomes and nanoparticles may be used for miRNA delivery.

One potential strategy is inactivating oncogenic miRNAs and another possible route in terms of therapy is in restoring down-regulated miRNAs that function as tumor suppressors. A third possible strategy is creating synthetic miRNAs to target mRNAs of genes known to contribute to cancer. Finally, a fourth possible strategy that has been proposed is utilizing miRNAs as agents to alter resistance to cytotoxic anti-cancer therapy.

Conclusion

miRNAs play a crucial role in the initiation and progression of human cancer. Research over the last few years has identified various mechanisms and targets involving miRNAs, significantly improving the knowledge of cancer biology. Evaluation of the potential of miRNAs as diagnostic and prognostic markers or therapeutic molecules or targets has just begun. The development of animal models will be useful for in vivo evaluation of miRNA molecules as anti-cancer drugs. It is predicted that miRNAs will bring about many revolutionary changes in cancer diagnosis, therapy and prevention.

(Reviewed by Dr Suresh Hedau, Scientist, Division of Molecular Oncology, Institute of Cytology & Preventive Oncology (ICMR), Noida)

CANCER AWARENESS

YOU ARE ALWAYS THE FIRST TO KNOW

Introduction

In Chinese medicine, a doctor is paid only so long as the patient remains well. If disease strikes, payment is stopped. It is this kind of emphasis on awareness and prevention that is required in India, if we are to "turn off the tap" on rising number of patients who throng the city hospitals. Cancer has become one of the ten leading causes of death in India. It is an important public health problem which is taking a heavy toll of precious human lives and destroying the families of the cancer patients due to mental agony and heavy costs of treatment. There are nearly 2.5 million cancer cases at any given point of time, with over 8 lakh new cases and 5.5 lakh deaths occurring each year due to this site. The country would see a 20% overall increase and 87,000 additional cases of cancer every year in men by 2020. Fresh cases of cancer annually among men will increase from 4.47 lakh in 2008 to 5.34 lakh by 2020. Over 70% of cases report for diagnosis and treatment services in advanced stage of disease, resulting in poor survival and high mortality rate.

In this era of medical cost containment, oncologists seek to develop not only better treatment for cancer but also effective programs for cancer prevention.

NCCP and Its Goals

Non-communicable diseases (NCD), such as coronary heart disease, diabetes, respiratory diseases (asthma) and cancer, have overtaken communicable diseases (CD) that governments traditionally concentrate their resources on. For the first time in human history, these NCDs pose more of a threat than CDs, which have been addressed by research and emphasis on sanitation, clean water and vector borne carriers.

To control cancer, the Government of India had launched a National Cancer Control Program (NCCP) in 1975, stressing on primary prevention and early detection of cancer:

- Primary prevention of tobacco related cancers;
- Secondary prevention of cancer of the uterine cervix, mouth, breast etc; and

- Tertiary prevention, including extension and strengthening of therapeutic services, pain relief on a national scale through regional cancer centers and medical colleges (including dental colleges).

Warning Signals

- Change in bowel or bladder habits
- A wound that does not heal
- Unusual bleeding or discharge
- Thickening or lump in the breast or elsewhere
- Indigestion or difficulty in swallowing
- Obvious change in wart or mole
- Nagging cough or hoarseness of voice

Risk Factors

It is often difficult to explain why one person develops cancer and another does not. However, scientific research shows that there are certain risk factors that increase the chances that a person will develop cancer. The most common risk factors for cancer include: age, ie, growing older; family history of cancer; poor diet, lack of physical activity, or being overweight; tobacco; alcohol; sunlight; ionizing radiation; certain chemicals and other substances; some viruses and bacteria; and certain hormones.

Many of these risk factors can be avoided. Others, such as family history, cannot be avoided. However, it is important to remember that cancer is not caused by an injury, such as a bump or a bruise; it is not contagious; having one or more risk factors does not necessarily mean that one will get cancer; some people are more sensitive than others to the known risk factors.

Common Cancers

The common cancers that can be easily detected at an early stage include:

- Oral cancers show up in the form of white patches (leucoplakia), black patches (melanoplakia), red patches (erythroplakia), submucous fibrosis and difficulty in fully opening the mouth. These can be easily detected during an oral examination.
- Cervical cancer can be detected through a pap smear, a painless test which involves scraping cells from the cervix during a pelvic examination. A microscopic examination of the smear can identify abnormal cells even in the pre cancerous stage (dysplasia).
- A firm lump, small changes or discharge from the nipples are early signs of breast tumor. At the clinic, women are instructed on how to perform an effective breast examination.

Recommendations for the Early Detection of Cancer in Average-Risk, Asymptomatic Individuals

| Cancer Site | Population | Test or Procedure |
|------------------------|-------------------------|--|
| Oral | Men & women | Examination by ENT surgeon. Most at risk: Users of tobacco |
| Breast | Women, aged 20+ | Breast self-examination; Clinical breast examination; Mammography |
| Colorectal | Men and women, aged 50+ | Guaiac-based fecal occult blood test; Fecal immunochemical test; Stool DNA test; Flexible sigmoidoscopy; Double-contrast barium enema; Colonoscopy; Computed tomography colonography |
| Prostate | Men, aged 50+ | Digital rectal examination; Prostate-specific antigen test |
| Cervix | Women, aged 18+ | Papanicolaou (Pap) test/ Visual inspection by Gynecologist VIA/ VILLI |
| Endometrial | Women at menopause | |
| Cancer-related checkup | Men and women, aged 20+ | Examination for cancers of the testicles, ovaries, lymph nodes, oral cavity, and skin, as well as health counseling regarding tobacco use, sun exposure, diet and nutrition, risk factors and environmental and occupational exposures |

Awareness Programs

There is highest incidence of cancers in the head and neck regions for men and cervix and breast for women. Many of these cancers are preventable and curable if they are caught at an early stage. Efforts have been laid down into developing ways to raise public awareness about cancer and how it can be prevented. Lectures and camps are regularly held at various sites.

Lectures: Cancer Awareness Program is the key thrust area and main activity for the control of cancer. People need to be informed that cancer is preventable, detectable at an early age and curable if treated promptly. Lectures impart warning signs and symptoms, known causes, risk factors, effect of lifestyle, diet and cancer correlation, dangers of tobacco abuse, cancer status in India, woman’s cancers, head and neck cancers, and myths as well as lead on to describing the screening procedures. Programs are organized through schools and colleges as well as at sites of social and welfare organizations throughout the country, involving delivery of lectures on cancer awareness. Trained volunteers deliver these talks supported by video cassettes and hold question and answer sessions. Literature on cancer is distributed free of cost on such occasions .

Camps/ Clinics/ OPDs: Most cases of cancer are detected in the advanced stages, when they are untreatable. Early Detection and Awareness program was developed from recognition of the need for a patient-friendly non-invasive screening mechanism that would be effective enough to detect cancer early, yet be non-intimidating so that people

would be willing to come in and be tested. Primary screening consists of examination by a panel of doctors including a surgeon, a physician, a gynecologist and an ENT specialist. Keeping warning signals in mind, medical checkup is done in clinics/ OPDs. Suspected cases are referred to hospitals for confirmation of diagnosis and further management.

Future Perspective

To combat cancer, Government of India has provided Rs 2,400 crore under the 11th Five Year Plan for the NCCP, almost 10-fold increase compared to the 10th plan allocation of Rs 252.95 crore. Under the NCCP, there are 27 Regional Cancer Centers in the country providing comprehensive cancer treatment facilities and carrying out cancer prevention and research activities. There are nearly 210 institutions in the country with cancer treatment facilities by radiotherapy through about 350 teletherapy units installed in the country. In the 11th Five-Year Plan, the focus would be on community based cancer prevention and control strategies. With the budget allocated under the 11th plan, the geographical gaps in the availability of cancer treatment facilities would be reduced to some extent.

(Reviewed by Mrs Jyotsna Govil, Hony Additional Secretary, Indian Cancer Society, New Delhi)

Cancer Detection Centre in Delhi
 42, Babar Road, Bengali Market
 New Delhi - 110001
 Phone: 011-23716941
 Monday-Friday: 9.00 AM - 12.00 Noon

RESEARCH & DEVELOPMENT

Complete Human Epigenome Mapped

Researchers at the Salk Institute have provided the first detailed map of the human epigenome, the layer of genetic control beyond the regulation inherent in the sequence of the genes themselves. Epigenetic changes play a crucial role in the development of cancer and some drugs that directly interact with the epigenome have been approved for the treatment of lymphoma and lung cancer and are now being tested against other cancer types.

The study compared the epigenomes of human embryonic stem cells and differentiated connective cells from the lung called fibroblasts, revealing a highly dynamic yet tightly controlled landscape of chemical signposts known as methyl-groups. The comparison brought to light a novel DNA methylation pattern unique to stem cells, which may explain how stem cells establish and maintain their pluripotent state. Being able to create high resolution maps of the human epigenome, the team will now begin to examine how it changes during normal development as well as examining a variety of disease states.

(Medical News Today, Oct 15, 2009)

Maternal-Fetal Transmission of Cancer

A collaborative study from UK and Japan has provided genetic evidence for woman to offspring transmission, in utero, of a leukemia cell clone. The Japanese mother was 28 years old at the time of her child's delivery and 36 days after the delivery, the mother was diagnosed with an advanced stage of leukemia and died. When the baby was eleven months old, she was brought to the hospital with swollen right cheek and was diagnosed as a case of lymphoma. To establish the link between maternal leukemia and child's lymphoma, the scientists used genetic fingerprinting and found that maternal and infant cancer clones shared the same unique BCR-ABL-1 genomic fusion sequence, indicating a shared, single-cell origin. Microsatellite markers in the infant cancer were all of maternal origin. Additionally, the infant maternally-derived cancer cells had a major deletion on one copy of chromosome 6p that included deletion of HLA alleles that were not inherited by the infant (i.e. foreign to the infant), suggesting a possible mechanism for immune evasion.

(PNAS, Oct 20, 2009)

Molecular Flag for Prostate Cancer

UK scientists at the University of Liverpool have discovered a molecular flag called heat shock protein-27 (HsP-27) in prostate tissue samples taken from 553 men at the time they were diagnosed with prostate cancer. Research showed that those who tested positive for HsP-27 at diagnosis were almost twice as likely to die from prostate cancer than men who did not have the protein, thus predicting survival from prostate cancer at diagnosis. These findings suggest that HsP-27, which identifies aggressive prostate cancer, would help to target active treatment to patients who need it, thereby avoiding unnecessary therapy. Currently, researchers are working on developing this finding into a blood test to monitor men with prostate cancer in order to determine when their individual disease needs treatment. HsP-27 is a key component of signaling pathways and new drugs could be developed to block these signals and halt the spread of prostate cancer cells. If further research shows that blocking these cell message systems is successful, it could provide a new treatment for aggressive forms of prostate cancer.

(Cancer Research UK, Sep 27, 2009)

New Molecular Strategies

According to cancer methylation database, PubMeth, of the 441 genes in the database, only 33 genes have been reported associated with head and neck (H&N) cancers. Henry Ford Hospital, US, study has identified 231 new genes associated with H&N cancer, opening the door to promising new molecular strategies for the early detection and treatment of H&N cancer. It may also help monitor disease progression and a patient's response to treatment.

To identify new genes, researchers used a whole-genome methylation approach to detect genes with altered promoter gene regions due to DNA methylation, a type of chemical modification of DNA, that allows the researchers to look for genetic abnormality within tumor samples. Using 5 DNA samples from tumor tissue, the researchers looked for 1043 possible genes. The whole-genome methylation approach revealed 231 potential new genes not previously reported in H&N cancer. Of these, 50% were present in three or more of the DNA samples and 20% were present in all 5 samples. Therefore, a validated H&N cancer-specific gene panel is likely to signify potential demethylation treatment targets.

(Science Daily, Oct 4, 2009)

NEW TECHNOLOGIES

NEW DRUGS

Bayer's Novel Anti-Cancer Compound

Bayer Health Care's novel anti-cancer compound Regorafenib (BAY73-4506) is a potent oral multi-kinase inhibitor with a kinase inhibition profile targeting angiogenic, stromal and oncogenic receptor tyrosine kinases (TK). The distinct anti-angiogenic profile includes inhibitor of both VEGFR2 and TIE2TK. Results of phase II, multicenter, open-label, single-arm study of regorafenib showed 31% partial response rate and 50% stabilization rate in patients with metastatic Renal Cell Carcinoma (RCC). This study suggests regorafenib as a potential first-line treatment option for patients with advanced RCC, which might eventually help physicians and patients manage this devastating disease. Regorafenib has been shown in preclinical studies to prevent the proliferation of tumor cell lines while promoting apoptosis by directly targeting several oncogenic TK receptors. Researchers are looking forward to continuing the comprehensive clinical development program for regorafenib, which could potentially represent a promising new treatment option for various tumors.

(Bayer Health Care, Sep 23, 2009)

Folotyn for Peripheral T-Cell Lymphoma

The first treatment, Folotyn (Pralatrexate) for Peripheral T-Cell Lymphoma has been approved by the US Food and Drug Administration (FDA) under the FDA's accelerated approval process for patients who have relapsed, or have not responded well to other forms of chemotherapy. The approval is based on evidence that it reduces tumor size, because tumor shrinkage is considered reasonably likely to predict a clinical benefit, such as extending the survival of cancer patients. The drug was designated as an orphan drug and to speed the drug's availability, Folotyn was granted priority review. Most common adverse reactions were irritation or sores of the mucous membranes, for which folate and vitamin B12 supplements should be taken. Folotyn can harm a fetus, so pregnant lady should be informed of the potential risk. Allos Therapeutics Inc., manufacturer of Folotyn, would conduct studies to confirm that tumor shrinkage actually does predict that patients would live longer.

(US FDA, Sep 27, 2009)

New Kidney Cancer Drug

The US Food and Drug Administration (FDA) has approved the oral kidney cancer medication Pazopanib (Votrient), the sixth drug to be approved for the disease since 2005. Pazopanib is an oral, once-daily angiogenesis inhibitor, targeting vascular endothelial growth factor receptor (VEGFR), platelet-derived growth factor receptor (PDGFR) and c-kit. By inhibiting VEGFR, PDGFR, and c-kit, Pazopanib may stop or slow the rate of tumor growth and development. The drug, which interferes with angiogenesis, is indicated for patients with advanced renal cell carcinoma. FDA approval of Pazopanib was based on data from a randomized, double-blind multicenter phase 3 study (n=435), showing that its use significantly increased progression-free survival relative to placebo (9.2 months vs 4.2 months; $P < .001$). Adverse events reported in 20% or more of patients receiving Pazopanib include diarrhea, hypertension, hair depigmentation, nausea, anorexia, and vomiting. It is currently also being studied in a number of different tumor types namely breast cancer, ovarian cancer, soft tissue sarcoma, non small cell lung cancer, cervical cancer and other solid tumors.

(Medscape Medical News, Oct 21, 2009)

Targeted Genetic Medicine

Epeius Biotechnologies Corporation announced results of its pioneering clinical studies of Regin-G, the world's first, and so far only tumor-targeted genetic medicine to be validated in the clinic. Three recent cases of stage IV metastatic cancer, namely osteosarcoma, prostate cancer, and pancreas cancer, demonstrated that Regin-G treatments alone led to clinical remission of disease in each of these poor prognosis patients. The profiles of the latter two patients signal the advent of Regin-G as the vanguard of a new class of exceedingly precise, selective, and effective anti-cancer agents, and which typify a newfound societal acceptance and acknowledgement of the real-world promise and potential of this uniquely-targeted genetic medicine. Medical oncologists around the world are recommending Regin-G as 'Best Care' for patients with refractory metastatic disease. It is approved for the treatment of all solid tumors in the Philippines, and has been granted both Orphan Drug Status for pancreas cancer, osteosarcoma and soft tissue sarcoma, and Fast Track Designation for pancreas cancer by the US FDA.

(Epeius Biotechnologies Corp., Oct 13, 2009)

DIAGNOSTICS

LightTouch Technology

Guided Therapeutics Inc (GT) has been granted \$2.5 million by National Cancer Institute to commercialize GT's LightTouch™ non-invasive cervical cancer detection technology. This technology systematically and rapidly scans the cervix to identify cancer and pre-cancer painlessly and non-invasively, by analyzing the wavelengths of light reflected from cervical tissue. The technology distinguishes between normal and diseased tissue, by detecting biochemical and morphological changes at the cellular level. Unlike Pap or HPV tests, the LightTouch test does not require a tissue sample or laboratory analysis and is designed to provide results immediately. The technology is designed as a device employing a single-use disposable patient interface. According to Guided Therapeutics, more than 3000 women have been tested with the LightTouch, including more than 1900 women who were evaluated as part of the FDA pivotal clinical trial. The non-invasive LightTouch test has the potential to be significantly more accurate when compared to tissue sample-based tests such as the Pap smear.

(Guided Therapeutics, Oct 7, 2009)

Response DX: Gastric Tests

Response Genetics, Inc. has launched Response DX: Gastric™ genetic test panel, a proprietary PCR-based diagnostic test, that offers physicians and their patients an objective way to chart a course of therapy during a very stressful time, the period between diagnosis and the start of treatment. Physician can better tailor treatment with gastric cancer and gastroesophageal junction cancer. The tests quantitatively analyse three genes: excision repair cross-complementing factor 1 (ERCC1), thymidylate synthase (TS) and human epidermal growth factor receptor 2 (HER2). ERCC1 expression correlates with sensitivity to platinum-based drugs, such as cisplatin, carboplatin and oxaliplatin; TS gene expression is for sensitivity to drug 5-fluorouracil and FOLFOX and HER 2 is a marker for sensitivity to trastuzumab. For gastric cancer patients to derive the maximum benefit from FOLFOX therapy, expression of both ERCC1 and TS genes must be at specific levels. However, if either marker is below a specific threshold, other therapies are available as alternative options.

(Response Genetics, Inc., Oct 1, 2009)

TECHNIQUES

Minimally Invasive Device

In Europe, Embozene™ microspheres are now approved for the treatment of liver cancer, uterine fibroids, tumors of the head, neck, torso, and skeletal system; for bleeding and trauma, and for reducing the amount of bleeding before any surgery other than in the central nervous system. A specially trained physician, an interventional radiologist, injects them inside a blood vessel to stop blood supply to a tumor or where there is unwanted bleeding. This minimally invasive treatment, called embolization, often replaces surgery. Embozene™ microspheres are tiny, round, hydrogel beads with a coating of Celonova's unique polymer, Polyzene®-F, known to be anti-inflammatory and bacterial-resistant. Four design features include biocompatibility, precise calibration, stable suspension, and structural stability. Celonova now has three distinct sizes of Embozene™ microspheres for physicians to use in the smallest blood vessels. Embozene™ microspheres are color-enhanced with a different color for each size for increased procedural safety, efficiency, and visibility. Patients experience lesser pain and have a speedy recovery.

(Celonova BioSciences, Inc., Oct 14, 2009)

New Vista for Cancer Surgery

Electrosurgery with electric scalpel coupled with mass-spectrometry technique developed by German-Hungarian research team is used for a new method called rapidevaporation ionization mass spectrometry (REIMS), to give tissue analysis, including data analysis to the surgeons during operation, in only fractions of a second. Advantage of electric scalpel is that while a cut is being made, blood vessels are closed and hemorrhaging eliminated. Advantage of mass spectrometry is that the tissue can be analysed during a surgical procedure. The electrosurgical instrument with a special pump sucks the vaporized cell components up through a tube and introduces the charge molecules into a mass spectrometer. Different tissue types demonstrate characteristic differences depending on lipid composition of cell membrane. During surgery, surgeons receive virtual real-time information about nature of tissue, helping in tumor localization and delimiting it from healthy tissue. REIMS provides information about the carcinoma stage and may spare patients from second surgery in future.

(Medical News Today, Oct 1, 2009)

BREAST CANCER

Breast Cancer Symposium

Research advances on the early detection, treatment and evaluation of breast cancer highlighted during “2009 Breast Cancer Symposium” held from October 8-10, 2009 at the San Francisco Marriott were:

- Majority of breast cancer deaths occur among women who don't receive regular mammography.
- Women under age 44 with ductal carcinoma in situ have a higher risk of recurrence.
- Adding low-cost ultrasound prior to surgery can reduce the need for second breast cancer surgery.
- New technique called tissue microarrays identifies breast cancer subtypes and predicts response to adjuvant paclitaxel (Taxol) chemotherapy.
- Women with small node-negative HER2+ breast tumors appear to benefit from adjuvant trastuzumab (Herceptin).
- Use of deep-inspiration breath hold technique reduces heart and lung exposure to radiation.
- PAM50 (50-gene qRT-PCR classifier) gene assay is highly prognostic for estrogen receptor positive, tamoxifen-treated breast cancer.
- Three forms of accelerated partial breast irradiation (interstitial brachytherapy, 3-D conformal external beam therapy and MammoSite) produce similar outcomes.
- In vitamin D deficiency prevalent in women being treated for breast cancer; high-dose supplementation can increase vitamin D blood levels than conventional low dose vitamin D supplementation.

(Medical News Today, Oct 9, 2009)

BREVAGEN™ Test

BREVAGEN™ breast cancer risk stratification test (formerly Mamma PLUS™) developed by Perlegen Sciences, is a novel genetic test panel that is an enhancement to current standard in breast cancer risk evaluation. Patient's blood sample is examined to detect the absence/ presence of certain common genetic variations associated with an increased risk for developing breast cancer. The test is designed to help physicians assess aggregate breast cancer risk from these genetic markers and factors from a standard clinical assessment based on a patient's family and personal history, thus identifying an individual woman's risk of developing breast cancer. The

test, clinically available in select US markets, may be useful for women at intermediate risk of developing breast cancer, including those who have undergone breast biopsies and could help physicians recommend alternative courses of action on a patient-by-patient basis.

(Perlegen Sciences, Sep 24, 2009)

Lymphedema

Breast cancer related lymphedema is a chronic, debilitating and often irreversible side effect of cancer treatment. It can be prevented or more effectively managed if detected early and treated by a physical therapist. Pre-operative assessments and post-operative follow up to detect lymphedema by using infrared technology to measure limb volume would allow for its early diagnosis and treatment. When detected early, light-grade compression sleeve and hand gauntlet would decrease early swelling and possibly prevent progression of lymphedema. These are prescribed for daily wear. Lymphedema is normally treated with complete decongestive therapy, requires the patient to attend daily therapy session for weeks and wear bulky compression bandages. Breast cancer patients should be encouraged to seek referral for physical therapy services before, during and after treatment and best outcomes are reached when they can be detected early or even prevented.

(American Physical Therapy Assoc, Oct 14, 2009)

Stem Cell from Menstrual Blood

Cryo-Cell International, Inc., a global leader in stem cell innovation is making progress in the fight against breast cancer through research and development using stem cells from menstrual blood. Its C'elle (SM) service was introduced in November 2007 as the first and only service that empowers women to collect and cryopreserve menstrual flow containing undifferentiated adult stem cells for future utilization by the donor or possibly their first-degree relatives in a manner similar to umbilical cord blood stem cells. Menstrual blood is proven to be a rich source of stem cells which proliferate rapidly and have the ability to become many different types of cells. Cryo-cell is currently in a research partnership with the National Institute of Health Clinical Centre, where research is underway to better understand the C'elle stem cells and their potential benefits for the treatment of breast cancer. Cryo-cell is supporting Susan G. Komen for the Cure® through C'elle in honor of National Breast Cancer Awareness Month.

(Cryo-Cell International, Inc, Oct 7, 2009)

CLINICAL TRIALS

Erbitux for Advanced Colorectal Cancer

According to new research findings in advanced bowel cancer patients with wild type KRAS tumors, targeted cancer drug Erbitux (Cetuximab) with FOLFIRI regimen of chemotherapy consisting of infused 5FU, leucovorin, irinotecan or FOLFOX 4 regimen consisting of infused 5 FU, leucovorin and oxaloplatin, gave a greater than two-fold increase in the chances of tumors responding, and significantly reduced the risk of disease worsening by over one-third (34%). This data is from a meta-analysis of 2 studies ie, the large phase III CRYSTAL study and the smaller phase II OPUS study. Over 1000 patients with advanced (metastatic) colorectal cancers participated and both studies investigated first line therapy with and without Erbitux. In 845 patients, researchers were able to confirm whether patient's tumors had the wild type KRAS gene, known to respond well to Erbitux, or a mutant KRAS gene which does not.

(Medical News Today, Sep 29, 2009)

Follicular Lymphoma

A phase III (PRIMA) international, multicentric, randomized study enrolled 1200 patients with previously untreated advanced follicular lymphoma. The study evaluated the efficacy and safety profile of maintenance Rituxan® (rituximab) in patients who responded to initial treatment with Rituxan plus chemotherapy (induction treatment). For initial treatment, either CHOP (cyclophosphamide, doxorubicin, vincristin, prednisolon), CVP (cyclophosphamide, vincristin, prednisolon) or FCM (fludarabine, cyclophosphamide, mitoxantrone) chemotherapy regimen was used. Patients who responded to Rituxan and chemotherapy were randomized to receive Rituxan alone, given once every 2 months for 2 years or observation alone. Results showed that those who continued receiving Rituxan alone after responding to Rituxan and chemotherapy lived longer without their disease worsening than those who did not continue to receive Rituxan. PRIMA met its endpoint during a pre-planned interim analysis, the study was stopped early on the recommendation of an independent data and safety monitoring board. The new steps for a potential new indication for Rituxan would be discussed with the US FDA and European regulatory authorities.

(Biogen Idec, Sep 17, 2009)

New Standard Treatment Option

In a phase III study funded by the German Cancer Foundation, targeted heat therapy offered new standard treatment option for soft tissue sarcoma. The trial involved 341 patients being treated at several centres in Europe and the United States for locally advanced soft tissue sarcomas that were at high risk of recurrence and spreading. All patients were given chemotherapy before and after surgery and radiotherapy. Half of them were randomly given targeted heat treatment along with chemotherapy. The technique known as regional hyperthermia, uses focused electromagnetic energy to warm the tissue in and around the tumor to between 40 and 43°Celsius. Study found that addition of the innovative heat technique more than doubled the proportion of patients whose tumors responded to chemotherapy without increasing toxicity. Patients were 30% more likely to be alive and cancer free almost 3 years after starting treatment, if their tumors were heated at the time they received chemotherapy. The results of this trial show that the field has now matured to the point where one must step up efforts to explore its potential to offer an entirely new way of treating locally advanced disease in several major cancers.

(The European Cancer Organization, Sep 23, 2009)

Ovarian Cancer

International multicentre CALYPSO trial presented at the 16th International meeting of the 'European Society of Gynaecological Oncology' in Belgrade, Serbia, showed that treating women with relapsed platinum-sensitive ovarian cancer with combined carboplatin and pegylated liposomal doxorubicin prolonged progression free survival and was associated with a lower risk of severe, long lasting nerve damage than standard carboplatin/paclitaxel treatment. Data from 986 patients treated in 16 countries in Europe, North America, the Middle East, Australia and New Zealand showed progression free survival of 11.3 months and 9.4 months respectively for the carboplatin/pegylated doxorubicin vs carboplatin/paclitaxel combinations in women with relapsed platinum sensitive disease (ovarian cancer that had relapsed more than six months after treatment with platinum-based chemotherapy). It has been pointed out that an unexpected advantage of adding doxorubicin to carboplatin was the reduction in sensitivity reactions to carboplatin seen in the novel treatment group compared to the normally seen with carboplatin alone or in other combinations.

(European Soc of Gynaecol Oncol, Oct 18, 2009)

WATCH-OUT

Breast Cancer Screening

Systems Inc U [US] has been issued patent No US2009240150(A1), entitled "Breast Cancer Screening With Adjunctive Ultrasound Mammography" on September 24, 2009. An adjunctive ultrasound mammography system and associated methods are described, comprising a scanning apparatus for facilitating standardized, repeatable breast ultrasound scans and further comprising an adjunctive ultrasound display apparatus configured for fast, intuitive viewing of adjunctive ultrasound data concurrently with x-ray mammogram information. In one preferred embodiment, thick-slice ultrasound images are displayed near an x-ray mammogram such that a screening radiologist can quickly view the thick-slice images for assistance in interpreting x-ray mammogram. Methods for concurrently acquiring and displaying vibrational resonance image (VDI) data are described. Computer-aided diagnosis (CAD) algorithms that incorporate acoustically-based feature vectors are described. Algorithms are also described that combine x-ray mammogram CAD results with adjunctive ultrasound CAD results without requiring complex image registrations therebetween. Barriers to acceptance and integration of ultrasound mammography into existing mass breast cancer screening environments are mitigated.

(European Patent Office, Oct 14, 2009)

Immune Response to PSA

Department of Health and Human Services, USA, has been assigned US patent No 7,598,225 entitled "Generation of immune response to prostate-specific antigen (PSA)", published on October 6, 2009. By using a recombinant viral vector, preferably a pox virus vector having at least one insertion site containing a DNA segment encoding PSA, or a cytotoxic T-cell eliciting epitope thereof, operably linked to a promoter capable of expression in the host, a specific humoral and cellular immune response to PSA can be generated. The method preferably comprises introducing a sufficient amount of the recombinant pox virus vector into a host to stimulate the immune response, and contacting the host with additional PSA at periodic intervals thereafter. The additional PSA, or a cytotoxic

T-cell eliciting epitope thereof, may be added by using a second pox virus vector from a different pox genus. In another embodiment, additional PSA can be added by contacting the host with PSA by a variety of other methods, including in one preferred embodiment adding PSA. The PSA may be formulated with an adjuvant or in a liposomal formulation.

(USPTO, Oct 15, 2009)

Prevention of Epithelial Cancer

Patent No EP 1389122/B1 entitled "Prevention of Epithelial Cancer" published on September 30, 2009 relates to use of a cyclooxygenase (COX) inhibitor, vitamin D₃ including analogues and metabolites thereof or calcium and combinations for preparation of a medicament for chemoprevention of epithelial cancer. It also relates to a method for reducing the effective dosage of a COX inhibitor such as acetylsalicylic acid (ASA) in a chemopreventive treatment of epithelial cancer, such as lung, bladder, prostate and/or gynecological cancer in a human by co-administration with a non-toxic dosage of a vitamin D₃ including analogues and metabolites thereof and, if so desired, Ca. In a presently preferred embodiment, the invention relates to the use of ASA, a vitamin D₃ and calcium together with a pharmaceutically acceptable carrier for preparation of a medicament for preventing initiation and/or progression of epithelial cancer.

(www.patentlens.net., Oct 15, 2009)

Taxane Compounds

The European Patent Office intends to grant European patent to Phyton Biotech GmbH covering methods of producing taxanes such as paclitaxel. Paclitaxel, the active ingredient in Bristol-Myers Squibb's TAXOL®, is useful in the treatment of breast, ovarian, lung, and other forms of cancer. Phyton's paclitaxel is produced in plant cell culture by a proprietary method developed as an alternative to harvesting tree bark or plantations as a taxane source. Patent will broadly cover methods for producing commercial levels of taxanes such as paclitaxel by cultivating cells of *Taxus chinensis*, a species of the yew tree in plant cell culture containing effective concentrations of silver and an auxin. The patent protects Phyton's European production of paclitaxel via its plant cell culture processes. The patent confirms Phyton's exclusive rights to produce paclitaxel pursuant to this process and may be asserted against any third party using the patented process in Europe, or importing products made by patented process into Europe.

(Phyton Biotech GmbH, Oct 13, 2009)

GLOBE SCAN

Plant-Based Drugs

Dr Josh Mylne from the Institute for Molecular Bioscience at University of Queensland has been presented with a Research Excellence Award to fund his work into using plants to produce pharmaceuticals. He has discovered a new type of natural machinery in sunflowers that can be used to manufacture small circular proteins for use as therapeutic drugs. Small proteins (peptides) can target cancer-causing enzymes with pinpoint precision, but they are susceptible to break down and are costly to manufacture. Circular peptides are ultrastable, so they can last a lot longer in biological fluids and have greater effect. Moreover, using the machinery of plants to produce these peptides will allow to manufacture a high volume at low cost. Dr Mylne has a peptide in mind for plant production, which targets an enzyme involved in prostate cancer. Early intervention and screening programs for prostate cancer are there, however drugs to treat advanced cases are still lacking. This work would open new field of research and next steps would be taken towards proof of concept for developing plant-based drugs and to begin testing them.

(Australia: University of Queensland, Oct 1, 2009)

Breast Cancer DNA Decoded

A team of Canadian researchers has decoded the genetic structure of metastasis lobular breast cancer that could lead to the development of new breast cancer treatments and therapies. Scientists at the BC Cancer Agency in British Columbia unlocked all 3 billion letters in the cancer's DNA sequence and identified all the mutations that caused the cancer to spread. Metastasis lobular breast cancer accounts for about 10% of all breast cancer. Researchers used the latest DNA sequencing technology to compare a single patient's lobular breast cancer tumor at 2 different times - nine years ago and this year. They found 32 mutations in the tumor and compared that with the original tumor's DNA. Only 5 were present in all the cells from original tumor, indicating that those mutations likely caused the disease. This research would enable to understand the cause of breast cancer and to develop personalized medicine for the patients.

(Canada: Tringle Business Journal, Oct 7, 2009)

Parasite Growth Hormone & Cancer

In northern Thailand, liver fluke (*Opisthorchis viverrini*) is most common and more than 7 million people are infected at any given time. About 17% of people infected with *O viverrini* could develop cholangiocarcinoma, one of the most fatal forms of liver cancer. The International Agency for Research on Cancer classifies the human liver fluke as Group 1 carcinogen, proven cause of cancer of the bile ducts. It has been known that certain proteins secreted by *O viverrini* cause cell growth, however, the identity of the protein was unknown. Researchers knew that the parasite secreted granulin, but they did not know that it could affect the human cells around it. Scientists from the Queensland Institute of Medical Research have found that the human liver fluke contributes to the development of liver cancer by secreting granulin, a growth hormone that is known to cause uncontrolled cell growth. This is the first research to show that growth hormone from a parasite can affect human cells. It is now thought that the granulin secreted by the parasite is a major contributing factor to developing bile duct cancer.

(Thailand: Medical News Today, Oct 11, 2009)

Reduce Tobacco Use

The American Cancer Society (ACS) and Free & Clear have announced a strategic business collaboration that would combine the legendary brand reach of world's leading voluntary health organization with technical strength of industry leader in tobacco cessation coaching. ACS is fighting tobacco domestically and globally through prevention and awareness and Free & Clear is helping individuals gain the knowledge and skills they need to overcome dependence on tobacco. The collaboration will more efficiently and effectively help tobacco users nationwide access evidence-based tobacco cessation services. Tobacco cessation services would be promoted by offering the Quit For Life Program to tobacco users through employers, health plans and state public health agencies. The two organizations would also work together on new product innovation, international market expansion opportunities, scientific research opportunities and ongoing development of protocols based on most current scientific evidence. They can invest more in complementary efforts to save lives by helping people stay well, by helping people get well, by finding cures and fighting back.

(USA: American Cancer Society, Oct 16, 2009)

ACTIVITIES OF RGCI&RC

CASE DISCUSSION: LUNG CANCER

Dr Maya Gottfried, Head of Lung Oncology Unit at Meir Medical Center in Kfar-Saba, Israel, visited Rajiv Gandhi Cancer Institute & Research Centre (RGCI&RC) on September 18, 2009. During Tumor Board meeting of the Institute, she delivered a talk on "Changing Paradigm in Management of Non Small Cell Lung Cancer". There were case presentations and interactive discussions on lung cancer with Dr Gottfried. It was attended by Medical Director, Consultants, DNB students and Research Officers of the Institute.

Lung cancer cases were presented by Dr Amit Dhiman and Dr Rajat Saha, DNB students, Medical Oncology. The first case was a 55 years old male, non smoker with no significant co-morbidity who had presented with complaints of cough with mild hemoptysis, right sided localized chest pain and progressive mild dyspnea for 3-4 months. PET-CT chest showed right lower lobe mass occluding the lower lobe bronchus. Right hilar, mediastinal and supraclavicular lymph node were enlarged. Multiple bony lesions were present which included bilateral (b/l) scapula, dorsal vertebrae and rib lesions. Bronchoscopy showed growth involving the right lower bronchus. Biopsy was moderately differentiated adenocarcinoma. Biochemistry tests were normal except increased alkaline phosphatase. Patient was given pemetrexed 500 mg/m² and cisplatin 75 mg/m² q 2 weekly and injection zoledronic acid 4 mg iv q 4 weekly. On interim evaluation, clinically symptomatic improvement was noticed, CT chest showed partial response. Patient was continued on the same chemotherapy regimen for another 3 cycles. On re-evaluation after completion of 6 cycles, PET scan showed near total metabolic complete response. Dr Gottfried said that as patient had shown good response to first line chemotherapy (pemetrexed), the patient should be given advantage of maintenance pemetrexed.

The second case was a 57 years old female, non smoker, diabetic on oral hypoglycemic agents. She presented with complaints of cough and progressive dyspnea since 2-3 months with good Performance Status (PS). X-ray chest showed left sided pleural effusion with left upper lobe opacity. CT chest showed left upper lobe mass with left sided moderate pleural effusion,

enlargement of left hilar and mediastinal lymph nodes, bilateral lung nodules. No bony lesions were seen. Pleural fluid tapping was done and pleural fluid cytology showed malignant cells suggestive of adenocarcinoma. For further management, Dr Gottfried said that in view of good PS, patient should be given advantage of chemotherapy or tyrosine kinase inhibitors should be started only if we are able to get EGFR mutation studies.

The third case was a 65 years old male, smoker, hypertensive, COAD. He presented with complaints of cough with minimal hemoptysis, left side localized chest pain, progressive dyspnea and significant weight loss since 3 months. x-ray of chest showed left mid-zone mass with multiple b/l lesions, CT chest showed left lower lobe mass with multiple b/l lung and pleural based lesions suggestive of metastasis, b/l extensive mediastinal lymph nodes. Bony lesions were found in dorsolumbar vertebrae and rib. Pleural nodule biopsy showed moderately differentiated adenocarcinoma. Biochemistry was normal except increased alkaline phosphatase. Patient was given gemcitabine 1.2 gm/m² day 1, day 8 and cisplatin 75 mg/m² on day 1 q 3 weekly along with injection zoledronic acid 4 mg iv q 4 weekly. Interim evaluation showed clinically mild symptomatic improvement and CT chest showed stable disease with no new lesions. For further management, Dr Gottfried favoured the continuation of same chemotherapy for 1 more cycle and then re-evaluation. In case of progression, the chemotherapy should be changed.

The last case was a 71 years old diabetic male patient who had chest pain since one month. He went to Cardiology Centre, where angioplasty was done on August 4, 2009. Routine CT chest revealed left hilar mass with pleural effusion and hence the case was referred to RGCI&RC. Patient had dysphagia with poor PS. After investigations, he was diagnosed as small cell lung cancer with mediastinal lymph nodes and pleural effusion. Patient was started on etoposide and carboplatin on August 19, 2009 and had received 2 cycles at 3 weekly intervals. Due to dysphagia, patient was started on hyperfractionated accelerated radiotherapy concurrently with chemotherapy. Dr Gottfried endorsed the treatment protocol and accepted that short treatment breaks due to neutropenia were inevitable in the current treatment scenario.

The Medical Director thanked Dr Gottfried for her visit to the Institute and giving valuable inputs on case discussions on lung cancer.

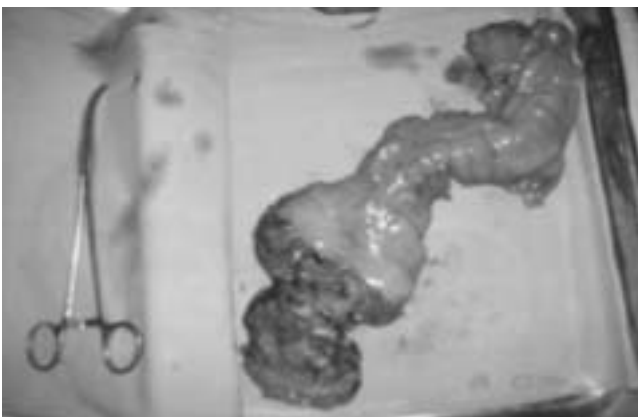CASE REPORTS FROM RGCI&RC

ANORECTAL MELANOMA

Case Summary

A 41-year old diabetic hypothyroid lady presented with mass protruding per rectum of 2 months duration associated with occasional bleeding. The biopsy revealed possibility of a pigmented neoplasm (? malignant melanoma). Contrast enhanced CT abdomen showed a small nodular intramural lesion in the anal canal with no perianal extension. Trans-ultrasound revealed pedunculated mass lesion from the posterior wall of anal canal with notching of the muscular layer as well as adventitia in the region of the vascular pedicle of mass and hence suspected transmural invasion.

She then presented to the Institute. Colonoscopy done revealed ulcerated polypoidal growth involving left lateral wall of anal canal. Histopathology exam (HPE) confirmed malignant melanoma. Wide local excision was done under spinal anaesthesia. HPE confirmed malignant melanoma of the anal canal with involved resected margins. She was planned and taken up for abdomino-perineal resection (APR) within a week. HPE of APR specimen revealed no residual tumour and all the 4 lymph nodes isolated were free of tumor deposits.



APR specimen of anorectal melanoma

The case was discussed in the multispeciality clinic. Since the role of adjuvant therapy in malignant melanoma was not well established, consensus favoured lifelong surveillance. Eight months after surgery, the patient is on followup with no evidence of disease on PET CT.

Discussion

Anorectal melanoma is rare, comprising less than 1% of all anorectal malignancies and 1% to 2% of melanomas.

Nevertheless, the anorectum is the most common site for development of primary melanoma in the alimentary tract. Owing to its low incidence, treatment of anorectal melanoma to date is not well defined. Thus, optimal surgical treatment for primary tumours is still controversial. For anorectal melanoma, this is the decision between life with a colostomy after APR or the risk of local recurrences with severe symptoms after wide local excision (WLE).

Meta-analyses with the compiled data of 426 patients failed to show the advantage of either approach with respect to overall survival (1). Nevertheless, there was a trend that local disease is more effectively controlled by APR than WLE (1-4). To this end, Thibault reported that isolated local recurrences after APR were rare (1). In all, 10 long-term survivors were reported by Brady et al in a cohort of 85 patients; nine of them received an APR; thus advocating APR (5). The mean tumour depth in patients with resectable disease undergoing APR was 7.5mm (range 0.5–20) compared with 6mm (range 4–9) in the group of patients treated with local procedures.

The prognosis of anorectal melanoma as for most other mucosal presentations of melanoma is poor (6-8), which seems to be due to late detection of the disease.

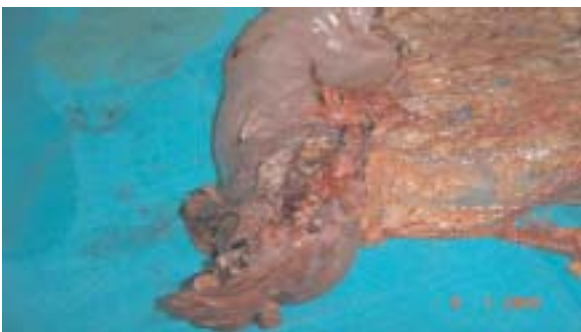References

1. Thibault C, Sagar P, Nivatvongs S, Ilstrup DM, Wolff BG (1997): Anorectal melanoma – an incurable disease. *Dis Colon Rectum*; 40(6); 661–68.
 2. Abbas JS, Karakousis CP, Holyoke D (1980): Anorectal melanoma- clinical features, recurrence and patient survival. *Int Surg*; 65; 423 - 426.
 3. Ross M, Pezzi C, Pezzi T, Meurer D, Hickey R, Balch C (1990): Patterns of failure in anorectal melanoma. *Arch Surg*; 125; 313–316.
 4. Roumen RMH (1996): Anorectal melanoma in The Netherlands- a report of 63 patients. *Eur J Surg Oncol*; 22; 598–601.
 5. Brady MS, Kavolius JP, Quan SHQ (1995): Anorectal melanoma, a 64-years experience at Memorial Sloan-Kettering Cancer Center. *Dis Colon Rectum*; 38(2); 146–151.
 6. Chung AF, Casey MJ, Flannery JT, Woodruff JM, Lewis JL (1980): Malignant melanoma of the vagina- a report of 19 cases. *Obstet Gynecol*; 55; 720–727.
 7. Going JJ, Kean DM (1989): Malignant melanoma of the nasal cavity. *J Laryngol Otol*; 103; 231–233.
 8. Kato T, Takematsu H, Tomita Y, Takahashi M, Abe R (1987): Malignant melanoma of mucous membranes. *Arch Dermatol*; 123; 216–220.
- (Dr Kapil Kumar, Senior Consultant, Dr Pankaj Pande, Consultant & Dr Veda Padma Priya, DNB Student, Dept of Surgical Oncology)

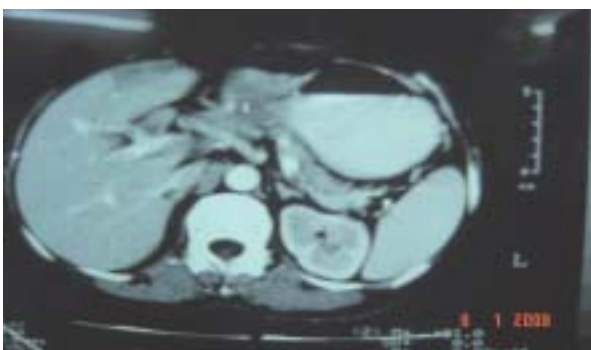GASTRIC TUBERCULOSIS

Case Summary

A 55-year old non-diabetic normotensive lady presented with anemia. Upper Gastrointestinal Endoscopy (UGIE) revealed ulceration at the incisura of stomach. Biopsy done thrice negative for malignancy. CECT abdomen revealed soft tissue mass in antropyloric region abutting head of pancreas and a wedge shaped hypodense area in segment IV of liver. Few enlarged aortocaval, portocaval and Lt paraaortic lymph nodes were seen. She then presented to the Institute. UGIE revealed nodular growth at incisura. Histopathology examination (HPE) favoured granulation tissue infiltrated by dense polymorphonuclear infiltrate with small foci of spindle cells. No evidence of malignancy seen. Repeat biopsy was inconclusive. CT guided FNAC from liver lesion was moderately cellular with benign hepatocytes and no evidence of malignancy. She was discussed in the multispeciality clinic and consensus favoured surgery in view of high suspicion of malignancy on UGIE. Intraoperatively intact nodes sent for frozen section were reported granulomatous lymphadenopathy. Sub-total gastrectomy with Roux-en-Y Gastro Jejunostomy + Jejunostomy + Feeding Jejunostomy was done. Post op HPE confirmed granulomatous ulcerative gastritis favouring tuberculosis. She was started on ATT on 10th post-operative day.



Specimen: Sub-total gastrectomy revealed lesion at incisura



CT abdomen: Soft tissue mass in antropyloric region

Discussion

Gastric tuberculosis (TB) is a rare entity even in India. It comprises only 0.2-1 % of patients with gastrointestinal (GI) TB. Postulated reasons for rarity of gastric TB are presence of acidic medium, scarcity of lymphoid tissue in stomach, integrity of gastric mucosa and active gastric motility. Possible routes of infection are by direct infection of mucosa, hematogenous spread and extension from neighbouring TB lesion. Early diagnosis is often missed due to varied non-specific manifestations of disease (1). It usually mimics peptic ulcer disease (2) or malignancy though occasionally it can manifest as pyrexia of unknown origin (3) or gastric outlet obstruction (1).

Tubercle formation in submucosa leads to papillary elevations of mucosa resulting in a protuberant mass, which in turn ulcerates due to a combination of localized endarteritis and lymphangitis (4). Ulcers may enlarge and produce undermined edges resembling carcinoma. Deep ulceration with little or no surrounding active fibrosis may give rise eventually to sub-serosal tubercles and adhesions.

Tuberculous lesions of stomach are usually located in lesser curvature of antrum and often involve the duodenum. Pyloric ulcers may cause gastric outflow obstruction. Fibrotic TB can resemble linitus plastica or lymphoma. A granulomatous mass may occur but this is least common appearance; sooner or later these granulomas will ulcerate and are usually diagnosed as malignant gastric ulcers (4). External pressure on stomach may be due to enlarged lymph nodes. Differential diagnoses to be considered besides gastric carcinoma, are Crohn's disease, sarcoidosis, syphilis, mycotic lesions and exposure to beryllium and silicates (5).

References

1. Okoro E O, Komolafe OF (1999): Gastric TB-unusual presentation in two patients. *Clin Radiol*; 54; 257-9 .
2. Chetri K, Prasad K K, Jain M, Chaudhari G(2000): Gastric TB presenting as non-healing ulcer-case report. *Trop Gastroenterol*; 21;180-1.
3. Salpeter S R, Shapiro R M (1991): Gastric TB presenting as PUO. *West J Med*; 155; 412-3.
4. A textbook of radiological diagnosis. 5th Ed, Vol 4. British Authors.
5. Deepak N Amarapurkar, Nikhil D Patel, Anjali D Amarapurkar (2003): Primary gastric TB - report of 5 cases. *BMC Gastroenterology*; 3;6.

(Dr Kapil Kumar, Senior Consultant, Dr Pankaj Pande, Consultant & Dr Veda Padma Priya, DNB Student, Dept of Surgical Oncology)